

## Vacuolar Myelinopathy in Waterfowl from a North Carolina Impoundment

Tom Augspurger,<sup>1, 4</sup> John R. Fischer,<sup>2</sup> Nancy J. Thomas,<sup>3</sup> L. Sileo,<sup>3</sup> Roger E. Brannian,<sup>3</sup> Kimberli J. G. Miller,<sup>3</sup> and Tonie E. Rocke<sup>3, 1</sup> US Fish and Wildlife Service, Ecological Services, Raleigh, North Carolina 27636-3726, USA; <sup>2</sup> Southeastern Cooperative Wildlife Disease Study, College of Veterinary Medicine, University of Georgia, Athens, Georgia 30602, USA; <sup>3</sup> US Geological Survey, National Wildlife Health Center, 6006 Schroeder Road, Madison, Wisconsin 53711, USA; <sup>4</sup> Corresponding author (email: tom\_augspurger@fws.gov)

**ABSTRACT:** Vacuolar myelinopathy was confirmed by light and electron microscopic examination of mallards (*Anas platyrhynchos*), ring-necked ducks (*Aythya collaris*), and buffleheads (*Bucephala albeola*) collected during an epizootic at Lake Surf in central North Carolina (USA) between November 1998 and February 1999. Clinical signs of affected birds were consistent with central nervous system impairment of motor function (incoordination, abnormal movement and posture, weakness, paralysis). This is the first report of this disease in wild waterfowl (Anseriformes).

**Key words:** Anseriformes, birds, intramyelinic edema, North Carolina, vacuolar myelinopathy, waterfowl.

Epizootic avian vacuolar myelinopathy (AVM) of wild birds was first described by Thomas et al. (1998) following morbidity and mortality of bald eagles (*Haliaeetus leucocephalus*) and American coots (*Fulica americana*) at an Arkansas (USA) reservoir. Lesions in the brain and spinal cord are characterized by intramyelinic vacuoles formed in the myelin sheaths by splitting of one or more myelin lamellae at the intraperiod line (Thomas et al., 1998). Clinical signs may include those associated with neurologic impairment, such as difficulty swimming or flying, incoordination, limb paresis, decreased withdrawal reflexes, and proprioceptive deficits (Larsen et al., 2002). While the etiology of AVM is unknown, the lesion and the epizootiology suggest a chemical substance, either man-made or natural (Fischer et al., 2002). Our objective is to document the first report of AVM in wild waterfowl (Anseriformes) as well as document the occurrence of AVM at Lake Surf, North Carolina (USA).

All cases described here originated from episodes of avian death and disease at Lake Surf (also called Woodlake), near

Vass, in Moore County, North Carolina (35°14'N, 79°12'W) (Fig. 1). Lake Surf is a 460 ha impoundment created in 1973; land cover prior to impoundment was forested wetland and the current shoreline consists of residential homes, golf courses, a dam, and pine forests. Crane Creek, Little Crane Creek, Beaver Creek, and Cypress Creek drain to Lake Surf, and the dominant cover types in the drainage basin are upland forests, pastures (horse farms), row crops (tobacco and vegetables), and forested wetlands.

Postmortem examinations were performed within 3 days of collection. Samples of liver and intestine were collected for culture of aerobic bacteria at 37 C on 5% sheep blood agar and eosin-methylene blue agar (DIFCO Laboratories, Detroit, Michigan, USA). Virus isolation attempts employed muscovy duck embryo fibroblast cell culture or embryonated eggs (Docherty and Slota, 1988). Heart blood was collected for assay in the mouse protection test for botulinum toxin (Quortrup and Sudheimer, 1943).

For light microscopy, portions of visceral organs and brain were removed and fixed in Bouin's fixative or 10% buffered formalin. Fixed tissues were routinely processed for paraffin embedding, sectioned at 5 µm, and stained with hematoxylin and eosin.

For electron microscopy, samples of optic lobe (all specimens) and sciatic nerve (some specimens) were placed in Karnovsky's fixative or 2% glutaraldehyde, 2% paraformaldehyde, and 0.2% picric acid in a 0.1 M cacodylate buffer (pH 7.2). Following fixation, samples were post-fixed in 1% osmium tetroxide, dehydrated in a se-

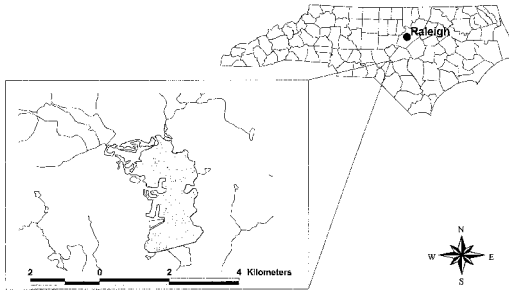


FIGURE 1. Location of Lake Surf (Woodlake), near Vass, Moore County, North Carolina.

ries of alcohols, stained *en bloc* with uranyl acetate, and embedded in epoxy resins. Sections 1  $\mu\text{m}$  thick were stained with toluidine blue and examined by light microscopy to select areas with vacuolar lesions of white matter. Ultrathin sections of these areas were stained with uranyl acetate and lead citrate and examined with a JEOL, Model JEM-1210 transmission electron microscope or Phillips 410 transmission electron microscope. Four cases are described here and are representative of the other cases in terms of clinical observations, necropsy findings, and diagnoses.

On 24 November 1998 an adult male mallard (*Anas platyrhynchos*) was observed on its back on shore. Upon approach by humans, the bird righted itself, flew a short distance, landed on its back, and struggled again to right itself. The duck was captured, euthanized, and sent to the US Geological Survey National Wildlife Health Center (NWHC, Madison, Wisconsin, USA) for diagnostic evaluation (case # 16065). There was no subcutaneous fat present, and the pectoral musculature was depressed 2–3 mm below the arc of the keel. On light microscopic examination, vacuolar degeneration of the white matter of the brain was apparent. Prominent vacuolation was observed in the cerebellum, brain stem, cerebrum, and optic chiasma. Significant microscopic lesions were not apparent in heart, kidney, ureter, liver, sciatic nerve, Meckel's diverticulum, or skull. Bacteria were not isolat-

ed from a sample of liver. Type C botulinum toxin was not detected in a sample of blood from the heart. Brain cholinesterase activity was determined, following the protocol of Hill and Fleming (1982), to be within normal reference range suggesting no recent significant exposure to carbamate and organophosphorous pesticides.

On 4 December 1998, a male ring-necked duck (*Aythya collaris*) was observed in the water listing to one side and with continuous paddling motions in unsuccessful attempts to right itself. When approached by humans, the duck swam awkwardly for approximately 3 m, never attempting to fly. This bird was captured and euthanized, and the brain of this specimen and a ring-necked duck found dead the same day were removed and placed in buffered formalin; the carcasses were chilled and transported to the Southeastern Cooperative Wildlife Disease Study (SCWDS, Athens, Georgia, USA) for diagnostic evaluation (case # 218-98). Gross examination revealed no significant lesions. The ducks were in good nutritional status. Light microscopic findings in the brains of both ducks consisted of moderate to marked vacuolation of the white matter. Lesions were especially severe in the optic lobe, white matter tracts within the cerebrum, and the cerebellar folia. Significant lesions were not apparent in sections of heart, skeletal muscle, lung, liver, kidney, spleen, adrenal gland, esophagus, proventriculus, and intestines. Bacteria were not isolated from samples of liver and intestine. Type C botulinum toxin was not detected in a sample of blood from the heart.

On 18 December 1998, a male mallard was found unable to fly and resting on the bank. This duck was unable to move its legs or feet, although it was able to weakly move its wings. It was in sternal recumbency with the head and neck in a normal position, and it appeared alert when approached. The bird was captured and transported the same day to SCWDS (case # 229-98) where it was euthanized and immediately necropsied. This bird was in

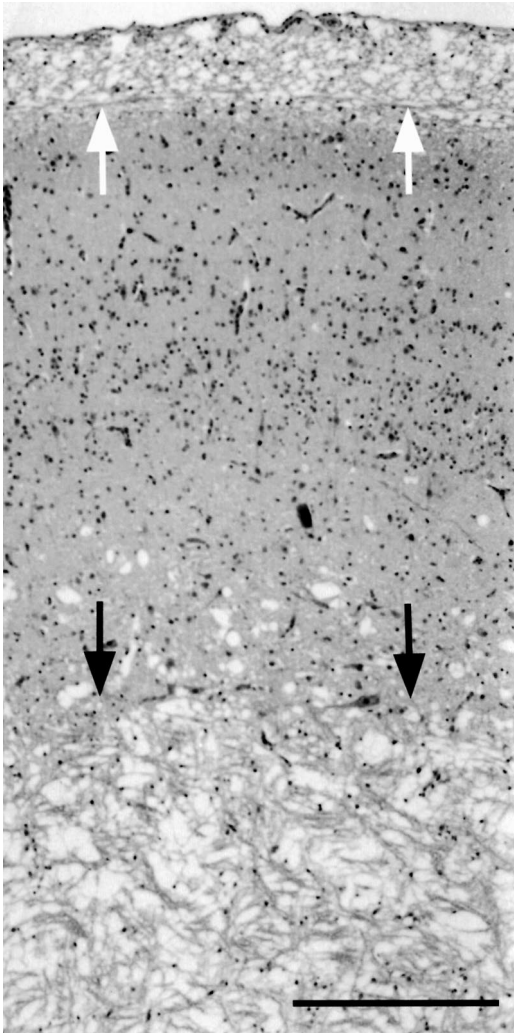


FIGURE 2. Optic lobe of mallard with vacuolar myelinopathy characterized by marked, diffuse, vacuolization of the white matter of the stratum opticum (white arrows) and the stratum album centrale (black arrows). H&E. Bar=165  $\mu$ m.

good nutritional status. External and internal examination revealed no significant gross lesions. Type C botulinum toxin was not detected in a sample of blood from the heart. Microscopically, marked vacuolation was present in the white matter of the brain (Fig. 2), spinal cord, and peripheral nerves. Lesions were especially severe in the brainstem, optic lobe of the brain, and white matter tracts in the cerebrum and were less severe in the cerebellar folia. In

the cerebral hemispheres, moderate vacuolar change was present multifocally in subcortical white matter and occasionally was associated with degeneration and necrosis of adjacent neurons. In the sciatic nerve and in visceral nerves in renal sections, there was moderate to marked dilation of the axonal sheaths with degeneration of the axons (Fig. 3). Significant lesions were not apparent in sections of heart, skeletal muscle, lung, trachea, esophagus, intestines, pancreas, spleen, and testes.

A diseased bufflehead (*Bucephala albeola*) was euthanized on 9 February 1999 and a dead bufflehead was retrieved 11 February 1999. The brain of each specimen was removed and placed in buffered formalin then transported to the NWHC for diagnostic evaluation (case # 16174). Light microscopic findings in the brains of both ducks consisted of moderate to marked vacuolation of the white matter.

Transmission electron microscopy of sections from the optic lobe of all specimens described here revealed moderate to marked vacuolation characterized by round to oval spaces enclosed by variably-thick myelin layers. The vacuoles were usually empty but some contained thin strands or whorls of myelin. The origin of some of these vacuoles could be traced to spaces between myelin lamellae where separation had taken place at the intraperiod line.

The case histories and results of gross, light microscopic, and electron microscopic examinations are consistent with a diagnosis of AVM (Thomas et al., 1998) in all of these specimens. The principal damage is seen in the myelin rather than the axon or perikaryon. As such, it is a true myelinopathy (Chang et al., 1992). Myelin is responsible for saltatory conduction of nerve impulses, and myelinopathy may result in a perturbation of normal nerve impulse transmission (Morrel, 1994). Thus, the clinical signs of nervous system impairment are consistent with the observed histopathologic lesions.

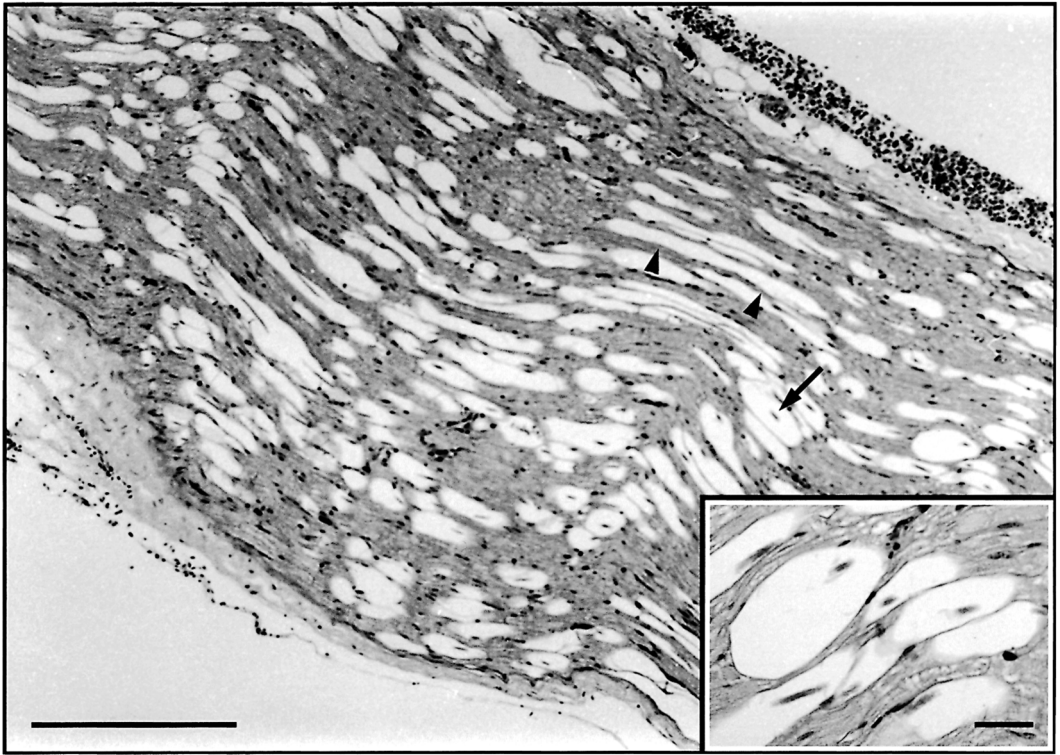


FIGURE 3. Sciatic nerve of mallard with vacuolar myelinopathy. There is marked, multifocal distention of the axonal sheaths (arrowheads) with degeneration of the axon (arrow). H&E. Bar=165  $\mu$ m.

Total numbers of dead or diseased waterfowl retrieved at Lake Surf between 6 November 1998 and 11 February 1999 included six mallards, two ring-necked ducks, and two buffleheads. Within that time period, we received reports of eight mallards and two ring-necked ducks that were uncoordinated and lethargic. The time and location of the reports made it likely that several of these waterfowl were collected later by us for examination. Dead and obviously impaired waterfowl represented <1% of the peak number of ring-necked ducks (420), <5% of the peak number of mallards (360), and approximately 25% of the highest 1 day count of buffleheads (nine) at Lake Surf in the winter of 1998. Additionally, AVM was diagnosed concurrently in numerous American coots at Lake Surf (J. R. Fischer, unpubl. data); the 1998 mortality of approximately 250 coots (from a wintering population estimated at 1,000) was among the highest

reported mortality in coots known for this site. A moribund bald eagle retrieved about 3 km from Lake Surf on 2 January 1999 (which died during rehabilitation) was also confirmed with AVM following electron microscopic examination of its brain (L. Sileo, unpubl. data). The effects of AVM on wintering populations of eagles, coots, and waterfowl are unknown.

With this report, AVM has been documented in three orders of wild avifauna: Gruiformes (rails, cranes, coots, and allies), Falconiformes (diurnal birds of prey), and Anseriformes (waterfowl). Documentation of AVM in waterfowl led to the use of sentinel mallards to study the epidemiology of the disease at this site (Rocke et al., 2002). Serial releases of sentinel mallards and American coots demonstrated that disease onset can be very rapid, appears to be seasonal, and is likely tied to environmental conditions at the lake (Rocke et al., 2002).

The addition of dabbling and diving ducks to the list of affected wild birds emphasizes the significance of the aquatic environment as a pathway of exposure for the disease agent. While coots primarily consume aquatic vegetation and algae and mallards feed on seeds and shoots of sedge, grass, aquatic vegetation, grain, acorns, and other mast, both species are also known to consume fish, tadpoles, crustaceans, snails, worms, aquatic and terrestrial insects, and other invertebrates (Allen, 1985, 1987). This gives the diet of the two species considerable overlap with that of ring-necked ducks and buffleheads, which primarily consume aquatic invertebrates but also eat aquatic vegetation (Gauthier, 1993; Hohman and Eberhardt, 1998). It is not known what the preferred food items of these species are on freshwater wintering grounds in North Carolina, such as Lake Surf. Documentation of local dietary preferences for these species and those that appear unaffected at this site (large numbers of ruddy ducks, *Oxyura jamaicensis*, are observed on Lake Surf in fall and winter) may help in pursuit of the etiology of AVM.

This is the first detailed report of AVM at Lake Surf (the only site in North Carolina where AVM has been documented); however, information retrieved from local wildlife management and veterinary diagnostic offices indicates it is likely that the disease occurred here as much as a decade earlier. At Lake Surf in October and November 1990, one American coot was found with paralysis of the legs; two were found with general lethargy, and two others were found dead (K. B. Knight, pers. comm.). Two diseased birds were taken to the Robbins Animal Disease Diagnostic Laboratory (Robbins, North Carolina) which reported malacia and edema in the cerebrum of one specimen, and softening and demyelination in the brain of the other (W. R. Wilson, Jr., pers. comm.). Preserved specimens from these birds were not retained by the diagnostic laboratory, so this case could not be re-examined in

light of current knowledge of AVM. However, the observation of coots with paralysis and myelin lesions at a site where AVM now has been documented suggests the disease had an earlier onset at Lake Surf.

We thank the residents and management of Woodlake Country Club for access to the site. We appreciate assistance from K. Knight (North Carolina Wildlife Resources Commission) and Dr. W. Wilson, DVM (North Carolina Department of Agriculture, Robbins Animal Disease Diagnostic Laboratory) for providing records from earlier investigations of coots from Lake Surf.

#### LITERATURE CITED

- ALLEN, A. W. 1985. Habitat suitability index models: American coot. US Fish and Wildlife Service, Biological Report 82(10.115), Washington, D.C., 17 pp.
- . 1987. Habitat suitability index models: Mallard. US Fish and Wildlife Service, Biological Report 82(10.132), Washington, D.C., 37 pp.
- CHANG, L. W. 1992. Basic histopathological alterations in the central and peripheral nervous systems: Classification, identification, approaches, and techniques. In *Neurotoxicology*. M. B. Abou-Donia (ed.). CRC Press, Boca Raton, Florida, pp. 223–252.
- DOCHERTY, D. E., AND P. G. SLOTA. 1988. Use of muscovy duck embryo fibroblasts for the isolation of viruses from wild birds. *Journal of Tissue Culture Methods* 11: 165–170.
- FISCHER, J. R., L. A. LEWIS, T. AUGSPURGER, AND T. E. ROCKE. 2002. Avian vacuolar myelinopathy: A newly recognized fatal neurological disease of eagles, waterfowl and other birds. *Transactions of the North American Wildlife and Natural Resources Conference* 67: 51–61.
- GAUTHIER, G. 1993. Bufflehead (*Bucephala albeola*). In *The birds of North America*, No. 67. A. Poole and F. Gill (eds.). The Academy of Natural Sciences, Philadelphia, Pennsylvania, 23 pp.
- HILL, E. F., AND W. J. FLEMING. 1982. Anticholinesterase poisoning of birds: Field monitoring and diagnosis of acute poisoning. *Environmental Toxicology and Chemistry* 1: 27–38.
- HOHMAN, W. L., AND R. T. EBERHARDT. 1998. Ring-necked duck (*Aythya collaris*). In *The birds of North America*, No. 329. A. Poole and F. Gill (eds.). The Academy of Natural Sciences, Philadelphia, Pennsylvania, 31 pp.
- LARSEN, R. S., F. B. NUTTER, T. AUGSPURGER, T. E. ROCKE, L. TOMLINSON, N. J. THOMAS, AND M. K.

- STOSKOPF. 2002. Clinical features of avian vacuolar myelinopathy in American coots. *Journal of the American Veterinary Medical Association* 221: 80–85.
- MORELL, P. 1994. Biochemical and molecular bases of myelinopathy. *In* Principles of neurotoxicology. L. W. Chang (ed.). Marcel Dekker, Inc. New York, New York, pp. 583–608.
- QUORTRUP, E. R., AND R. L. SUDHEIMER. 1943. Detection of botulism toxin in the blood stream of wild ducks. *Journal of the American Veterinary Medical Association* 102: 264–266.
- ROCKE, T. E., N. J. THOMAS, T. AUGSPURGER, AND K. MILLER. 2002. Epizootiologic studies of avian vacuolar myelinopathy in waterbirds. *Journal of Wildlife Diseases* 38: 678–684.
- THOMAS, N. J., C. U. METEYER, AND L. SILEO. 1998. Epizootic vacuolar myelinopathy of the central nervous system of bald eagles (*Haliaeetus leucocephalus*) and American coots (*Fulica americana*). *Veterinary Pathology* 35: 479–487.

*Received for publication 13 August 2002.*