

## CLINICAL PRACTICE

## Rotator-Cuff Failure

Frederick A. Matsen III, M.D.

*This Journal feature begins with a case vignette highlighting a common clinical problem. Evidence supporting various strategies is then presented, followed by a review of formal guidelines, when they exist. The article ends with the author's clinical recommendations.*

**A 63-year-old woman presents with a 2-year history of progressive weakness and discomfort in her right shoulder, especially when she puts dishes on the top shelf in her kitchen. She is otherwise healthy and has had no injuries. Her physician diagnosed “bursitis” and gave her four subacromial corticosteroid injections; the first two seemed to relieve her symptoms temporarily, but the last two were ineffective. Physical examination reveals some atrophy of the muscles of the right shoulder and weakness when her right arm is elevated. Magnetic resonance imaging (MRI) reveals a large defect in the rotator cuff. How should her case be managed?**

## THE CLINICAL PROBLEM

From the Department of Orthopaedics and Sports Medicine, University of Washington, Seattle.

N Engl J Med 2008;358:2138-47.  
Copyright © 2008 Massachusetts Medical Society.

The rotator cuff is a synthesis of the capsule of the glenohumeral joint with the tendons of the subscapularis, supraspinatus, infraspinatus, and teres minor muscles (Fig. 1).<sup>1</sup> The rotator-cuff mechanism precisely centers the humeral head by compressing it into the glenoid concavity. The individual muscles of the cuff help to provide strength in arm movement: the subscapularis in internal rotation, the supraspinatus in elevation, and the infraspinatus and teres minor in external rotation.

Failure of the rotator-cuff tendons due to either tear or wear is the most common clinical problem of the shoulder, accounting for more than 4.5 million physician visits per year in the United States.<sup>2</sup> Failure of the cuff tendon may result from a major injury, but more commonly it results from age-related attrition of the tendons, typically starting with the undersurface of the anterior aspect of the supraspinatus (Fig. 1 and 2 of the Supplementary Appendix, available with the full text of this article at [www.nejm.org](http://www.nejm.org)).<sup>3</sup> Failure of the rotator cuff may progress to involve the full thickness of the tendinous insertions of the supraspinatus and then may extend to involve the infraspinatus and the subscapularis.

The natural history of degenerative cuff-tendon failure is one of age-related progression.<sup>4</sup> Imaging studies reveal that 30% of asymptomatic persons over 60 years of age<sup>5</sup> and 65% of asymptomatic persons over 70 years of age<sup>6</sup> have rotator-cuff defects. The rate of progression may be slow; patients with moderately symptomatic, massive rotator-cuff tears have been found to maintain satisfactory shoulder function for at least 4 years.<sup>7</sup>

Cuff defects are also more frequent in obese persons.<sup>8</sup> Although corticosteroid injections have not been shown to increase the risk of cuff failure, there is evidence that injection of corticosteroids in and around tendons and ligaments can alter their collagen composition, strength, and ability to heal.<sup>9-11</sup> Nicotine also may compromise the ability of tendons to heal and attach to bone.<sup>12</sup>

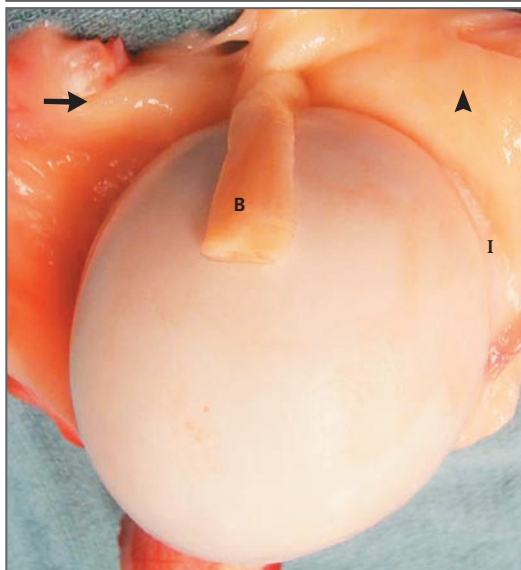
## STRATEGIES AND EVIDENCE

## EVALUATION

The clinical manifestations of full-thickness, degenerative rotator-cuff failure vary widely among patients (Table 1).<sup>13,14</sup> Patients with acute, traumatic, full-thickness cuff tears may experience the sudden onset of weakness with elevation of the arm after an injury in which the arm has been forced to the side (e.g., during a fall while skiing with the arm out to the side or on catching a heavy falling object with the extended arm). Patients with chronic degenerative cuff defects may notice a gradual onset of shoulder weakness, often accompanied by pain and crepitus on active movement<sup>4</sup>; however, many degenerative rotator-cuff defects are asymptomatic.<sup>13,15</sup>

The examination of the shoulder should include observation for atrophy of the deltoid, supraspinatus, or infraspinatus or a combination of these muscles. Palpation at the anterior greater tuberosity may reveal a defect in the cuff-tendon attachment (Fig. 2A). Palpation below the acromion as the arm is rotated may reveal crepitance from the edges of the torn cuff (Fig. 2B). Pain or weakness on isometric testing of arm elevation suggests involvement of the supraspinatus (Fig. 2C). Pain or weakness on isometric testing of internal rotation suggests involvement of the subscapularis (Fig. 2D), and during external rotation pain or weakness suggests involvement of the infraspinatus (Fig. 2E). The range of passive motion may be limited in shoulders with cuff defects; the limitation of internal rotation on abduction is particularly common in partial-thickness rotator-cuff lesions (Fig. 2F).

Because the cuff mechanism is the primary stabilizer of the shoulder, major cuff defects may be associated with instability in the anterior, posterior, or superior direction. In a severe form of instability known as anterosuperior escape, the humeral head slides out anteriorly on attempted elevation because of wear or surgical compromise of the coracoacromial arch.<sup>16,17</sup> When the humeral head is no longer stabilized in the glenoid concavity, contraction of the deltoid muscle is ineffective in elevating of the arm away from the side, leading to a finding known as pseudoparalysis of the shoulder.<sup>16,17</sup>



**Figure 1. Anatomy of the Rotator Cuff.**

In this view of the rotator cuff from inside the joint, the sectioned long head of the biceps is draped across the humeral head. The subscapularis tendon (arrow) approaches the humerus from the left, the supraspinatus (arrowhead) from the top to the right of the biceps (B), and the infraspinatus (I) from the right below the supraspinatus. The slip of supraspinatus forms a roof over the biceps tendon.

## IMAGING

Plain films of the shoulder may show upward displacement of the humeral head relative to the glenoid and narrowing of the interval or even contact between the acromion and the humeral head in patients with chronic cuff failure. Plain imaging may also reveal an alternative cause of shoulder pain such as degenerative arthritis of the glenohumeral joint. Both MRI (Fig. 3) and ultrasonography (Fig. 4) may be useful in directly evaluating the status of the rotator-cuff tendons.<sup>18</sup> In a study comparing the results of imaging with findings at arthroscopy, ultrasonography and MRI were each almost 90% accurate in diagnosing full-thickness and partial-thickness tears. The sensitivities and positive predictive values of both tests were high (97%), but the specificities were only modest (67%). In another study, which used open or arthroscopic operative findings as the gold standard, ultrasonography and MRI each correctly identified approximately 90% of full-

**Table 1. Differential Diagnosis of Rotator-Cuff Lesions.**

Diagnosis	History	Findings			
		Physical Examination	Plain-Film Radiographic Assessment	MRI or Ultrasonographic Examination	Electromyographic Examination
Partial-thickness acute tear	Fall or sudden attempt to lift the arm, followed by pain	Pain on resisted elevation of the arm	Normal findings	Thinning of tendon at insertion, with defect in the deep aspect of the tendon	Normal findings
Full-thickness acute tear	Sudden loss of shoulder strength after a fall or sudden attempt to lift the arm	Weakness of the arm during elevation and possibly during external rotation, palpable defect in tendon insertion	Normal findings	Full-thickness defect in cuff tendon	Normal findings
Acute fracture of tuberosity	Sudden loss of shoulder strength after a definite injury	Weakness of the arm during elevation and possibly during external rotation	Tuberosity fracture	Tuberosity fracture	Normal findings
Degenerative rotator-cuff failure	Insidious onset of shoulder weakness without major injury	Weakness of the arm during elevation and possibly during external rotation, palpable defect in tendon insertion	Normal or narrowed space between humeral head and acromion	Full-thickness defect in cuff tendon or tendons; atrophy, fatty degeneration, or both of cuff musculature	Normal findings
Anterosuperior escape, pseudoparesis, or both	Inability to raise the arm away from the side	Severe weakness, anterior and superior movement of humeral head on attempted elevation of the arm	Superior displacement of humeral head relative to glenoid and acromion	Supraspinatus and often infraspinatus tendons not visible	Normal findings
Frozen shoulder	Shoulder pain and stiffness, often without an injury	Limited range of motion, especially in internal rotation of the abducted arm, external rotation, and when the patient reaches up the back	Normal findings	Normal findings (contrast-enhanced MRI may show obliteration of normal axillary recess)	Normal findings
Glenohumeral arthritis	Progressive onset of pain and stiffness	Limited range of motion, especially during external rotation and elevation; bone-on-bone crepitance	Joint-space narrowing, osteophytes, sclerosis	Cuff tendons usually intact	Normal findings

Bursitis, subacromial abrasion	Pain and catching without weakness	Crepitance on rotation of the arm	Normal findings	Normal findings	Normal findings
Acute calcific tendinitis	Severe pain at rest, difficulty moving the arm	Local tenderness over supraspinatus tendon insertion, pain on elevation of the arm	Normal findings	Calcific density in supraspinatus tendon near insertion	Normal findings
Cervical radiculopathy	Pain above the shoulder, hand numbness, dysesthesia	Shoulder and arm symptoms exacerbated by turning the head or leaning the head to the side, weakness, atrophy, loss of reflexes (often in C5 or C6 distribution)	Normal findings	Normal findings on shoulder films, cervical spondylosis	C5 or C6 findings
Brachial neuritis (Parsonage-Turner syndrome)	Atraumatic onset of pain in nerve distribution, followed by weakness	Weakness of the supraspinatus and infraspinatus due to involvement of the suprascapular nerve	Normal findings	Normal findings	Peripheral neuropathy
Spinoglenoid notch cyst (ganglion)	Onset of weakness in suprascapular nerve distribution	Weakness of supraspinatus, infraspinatus, or both	Normal findings	Normal findings	Suprascapular denervation

thickness cuff defects, 70% of partial-thickness cuff defects, and 80% of normal tendons.<sup>19</sup>

Decisions regarding the need for imaging should be based on whether the results are likely to affect treatment. For example, because of the need for prompt repair of an acute full-thickness tear, an expedited ultrasound or MRI study is warranted in a patient who cannot raise his or her arm after a fall.<sup>20-22</sup> However, imaging of the cuff tendon is unlikely to change the initial care of an elderly patient who has no history of an injury and who reports long-standing weakness, pain, and stiffness in the shoulder that are suggestive of degenerative cuff failure.

**TREATMENT**

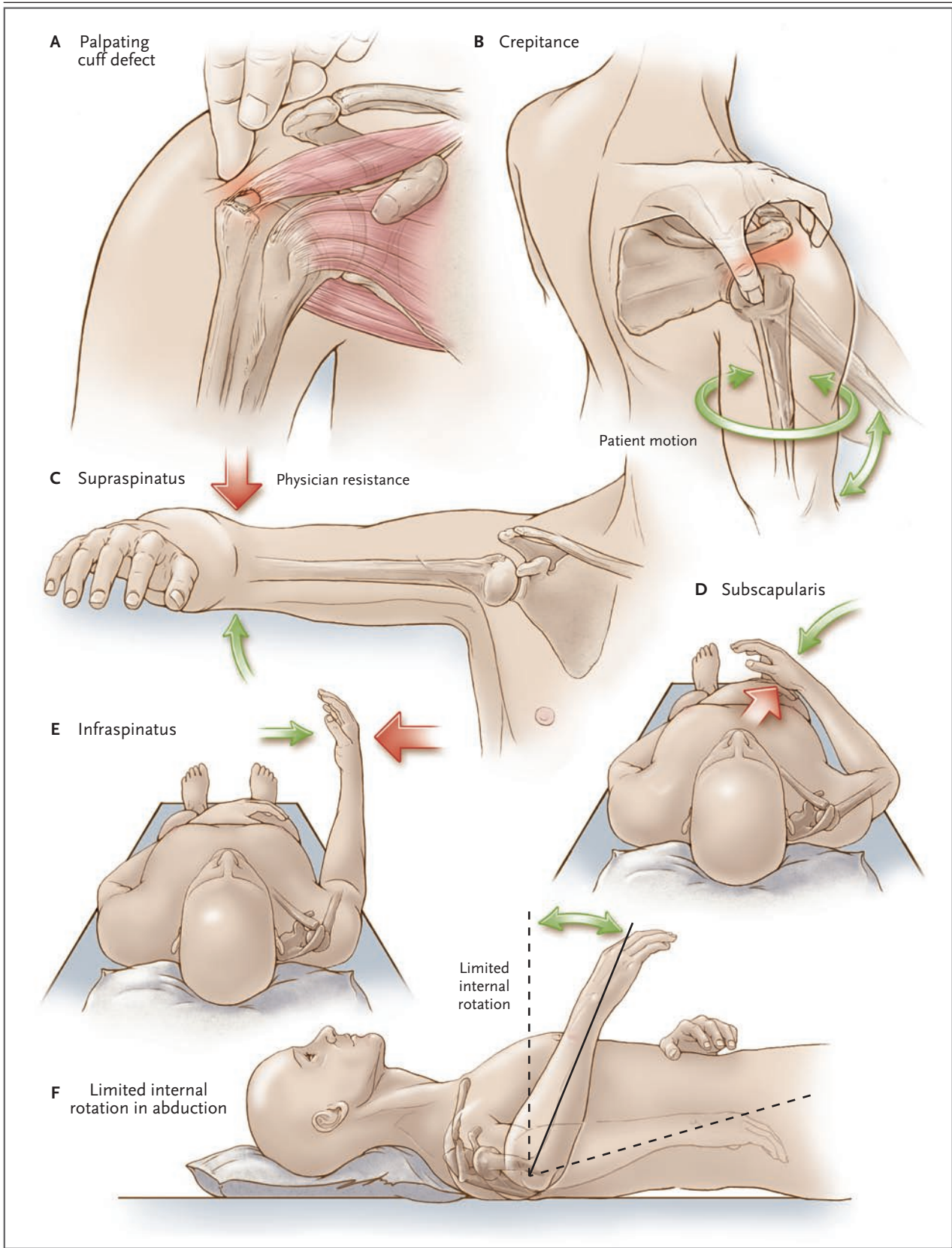
The treatment of various types of rotator-cuff lesions is summarized in Table 2. Few randomized trials have compared the effectiveness of different approaches to the management of rotator-cuff lesions, and none have directly compared surgical with nonsurgical intervention. A Cochrane review of various common interventions for rotator-cuff lesions<sup>23</sup> concluded that there were insufficient data to provide support for or refute their use.<sup>2</sup> Most studies have been limited by the lack of a control group, the types of outcome data reported (which have rarely included assessment of both the subjective benefits to the patient and the objective assessment of the integrity of the rotator-cuff tendons), the lack of long-term follow-up of all prospectively enrolled patients, and the questionable generalizability of studies performed by expert surgeons in major centers to general practice.<sup>24</sup> Therefore, the approach to the management of cuff lesions is largely based on clinical experience, an understanding of the anatomy, and the management of tendon failure at other sites, such as the hand and knee.

*Acute Complete Tears*

As is the case with the acute rupture of any major tendon, acute traumatic ruptures of the rotator cuff are best repaired as soon as possible, ideally within 6 weeks after injury.<sup>21,25-32</sup> Prolonged observation and nonsurgical management allow the detached tendon to retract and resorb while the muscle atrophies.<sup>20-22,33,34</sup>

*Partial-Thickness Rotator-Cuff Tendon Defects*

In contrast to acute full-thickness cuff tears, acute partial-thickness or chronic partial-thick-



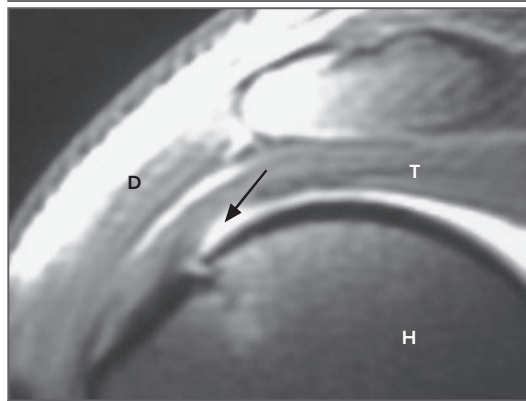
**Figure 2 (facing page). Examination of a Patient with a Suspected Rotator-Cuff Injury.**

Defects in the rotator cuff often can be palpated just lateral to the acromion when the patient's arm is at the side and slightly extended (Panel A). Gently rotating the arm can increase the sensitivity of this palpation. Roughness between the rotator cuff and the coracoacromial arch can be assessed by palpating the shoulder for crepitation while the patient's arm is passively rotated (Panel B). The integrity of the supraspinatus attachment to the greater tuberosity of the humerus is examined by having the patient isometrically press up against resistance while the arm is held at 90 degrees of elevation and internal rotation (Panel C). A defect of the supraspinatus tendon can produce pain or weakness on this test. The integrity of the subscapularis attachment to the lesser tuberosity of the humerus is examined by having the patient isometrically rotate the arm inward toward the abdomen while the forearm is flexed to a 90-degree angle (Panel D). A defect of the subscapularis tendon can produce pain or weakness on this test. The integrity of the infraspinatus attachment to the greater tuberosity of the humerus is examined by having the patient isometrically rotate the arm outward against resistance while the arm is held at the side with the forearm pointing forward and flexed to a 90-degree angle (Panel E). A defect of the infraspinatus tendon can produce pain or weakness on this test. Limitation of internal rotation is a common manifestation of rotator-cuff injury (Panel F). The most sensitive test involves placing the arm of the supine patient at 90 degrees of abduction away from the side and measuring the degrees of internal rotation from the position with the forearm vertical (0 degrees of internal rotation).

ness cuff tears often improve with nonsurgical management because the part of the tendon remaining intact prevents retraction and muscle atrophy (see Fig. 1 and 2 of the Supplementary Appendix). A program of range-of-motion exercises may help resolve the stiffness in adduction across the body, in internal rotation up the patient's back, and especially in internal rotation with the arm in abduction. Patients in whom the symptoms of a partial cuff tear are refractory to this stretching program may benefit from débridement of the lesion, smoothing of the humeroscapular motion interface, and curettage of the deep surface of the tendon attachment. In a series of patients who underwent débridement of partial-thickness defects of the rotator cuff without acromioplasty, the results were considered satisfactory by 87% of the patients.<sup>25,35</sup>

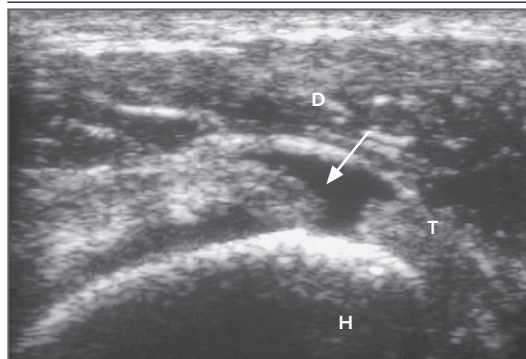
*Chronic, Full-Thickness, Degenerative Tendon Defects*

Most chronic, full-thickness, degenerative tendon defects are best managed without surgery. Non-



**Figure 3. Coronal MRI Scan of the Right Supraspinatus Tendon.**

The tendon has an articular-surface partial-thickness defect (arrow). D denotes deltoid, H humeral head, and T tendon. (Courtesy of Michael Richardson, Department of Radiology, University of Washington, Seattle.)



**Figure 4. Coronal Ultrasonographic Image of the Left Supraspinatus Tendon.**

The tendon has a full-thickness defect (arrow). D denotes deltoid, H humeral head, and T tendon. (Courtesy of Michael Richardson, Department of Radiology, University of Washington, Seattle.)

surgical approaches include treatment with nonsteroidal antiinflammatory drugs (NSAIDs) or acetaminophen for discomfort, activity modification, and gentle stretching and strengthening exercises for the muscles that remain intact. Although data are lacking from randomized trials assessing the benefits of exercise therapy for full-thickness, degenerative defects, case series and case reports have shown improvement in comfort and function with exercise.<sup>36</sup>

In a Cochrane review of placebo-controlled, randomized trials of the use of subacromial injection of corticosteroids for rotator-cuff disease,

**Table 2. Treatment of Rotator-Cuff Lesions.**

Diagnosis	Nonsurgical Management	Surgical Management
Acute rotator-cuff tear	Usually not recommended in active persons	Prompt surgical repair in active persons
Partial-thickness rotator-cuff lesion	Flexibility exercises to eliminate shoulder tightness, especially of the posterior capsule	Surgical repair often not needed; smoothing of humeroscapular motion interface, cuff curettage, or both may be considered
Degenerative rotator-cuff failure without arthritis	Flexibility exercises to restore range of motion, gentle progressive strengthening exercises to increase shoulder function	Surgical repair often not possible; surgical repair may be considered if quality and quantity of tissue are sufficient for durable repair — otherwise, smoothing of humeroscapular motion interface is considered
Arthritis of humeral head and chronic, massive rotator-cuff defect	Flexibility exercises to restore range of motion, gentle progressive strengthening exercises to increase shoulder function	Humeral hemiarthroplasty with careful preservation of coracoacromial arch
Anterosuperior escape, pseudoparesis, or both	Flexibility exercises to restore range of motion, gentle progressive strengthening exercises to increase shoulder function	Reverse total shoulder arthroplasty to provide necessary glenohumeral stability <sup>16</sup>

some trials showed a modest benefit with this intervention; however, pooled results of three trials comparing subacromial corticosteroid injection with NSAIDs showed no significant benefit of injection. Overall, the authors concluded that the effects of subacromial corticosteroid injection for rotator-cuff disease appeared to be slight and not sustained.<sup>37</sup> Another Cochrane review showed no evidence of a significant benefit of corticosteroid injection in patients with rotator-cuff tears.<sup>23</sup> Because corticosteroid injections may adversely affect tendon quality and their benefit is uncertain, repeated use of injections is discouraged, except in cases in which surgery is not considered an option, the response to other nonsurgical interventions is inadequate, and there is a perceived improvement in symptoms with injection. Other approaches, such as electrotherapy, therapeutic ultrasonography, acupuncture, injection of hyaluronic acid, and shock-wave therapy, have also been used in patients with rotator-cuff failure, but these methods have not been rigorously studied, and the indications and benefits are unclear.<sup>23</sup>

If symptoms persist in spite of nonsurgical measures and the clinical evaluation suggests that the cuff is repairable, surgical repair can be considered. Factors that favor durable surgical reattachment of a detached rotator-cuff tendon include an age of less than 60 years, a traumatic onset of weakness, a short duration of symptoms (e.g., <2 months), no history of smoking, good general health, receipt of only a few (e.g., <4) cortisone injections, no previous shoulder surgery, no detection of atrophy of the muscles

on physical examination, stability of the shoulder, a good range of motion in the shoulder, and MRI or ultrasound findings that show minimal retraction, good tendon quality, and minimal muscle atrophy. Reports on the results of surgery for rotator-cuff repair indicate that more than 75% of repairs of defects that involve only the supraspinatus remain intact at 5 years and are associated with improved comfort and function, whereas less than 50% of repairs of defects that involve the supraspinatus and infraspinatus remain intact at 5 years. Improved comfort may be achieved even if the repair does not remain intact.<sup>26-32,38-41</sup> Outcomes have been reported to be best when the repair is performed by a surgeon who is experienced in rotator-cuff reconstruction.<sup>42</sup>

The risks associated with surgery for rotator-cuff repair include infection, postsurgical adhesions with loss of motion, damage to the deltoid from the surgical approach, injury to the axillary nerve, prominent sutures or fixation devices causing roughness in the humeroscapular motion interface (resulting in pain and reduced range of motion), and damage to the coracoacromial arch from acromial resection, leading to anterosuperior escape. These complications are rare in centers with experience in this type of surgery.<sup>26-28,30,32</sup> The risk of a retear after a repair varies substantially with the quality of the tendon and the size of the tear.<sup>32</sup>

The approach to and duration of rehabilitation after rotator-cuff repair depend on the quality of the tendon that was sutured back to the bone and the security of fixation. Rotator-cuff tendons

that failed with minimal injury are at high risk for repeat failure after surgical repair. Two to six sutures are generally used to attach the tendon to the bone; any of these sutures may pull through the tendon with tension overload. All positions and motions of the shoulder apply some load to the repaired cuff. For all these reasons, the surgically repaired cuff must be protected from active use and from falls for at least 3 months after repair, allowing the bone the opportunity to attach to the tendon. The total period of rehabilitation after rotator-cuff repair is often as long as 1 year, during which time the use of the arm remains limited.<sup>43</sup> The recovery period may be shorter with secure repair of acute rotator-cuff defects with good-quality tissue.

In patients in whom the cuff appears to be irreparable but who are bothered by painful crepitance or stiffness, surgery to smooth the humeroscapular motion interface and remove restricting adhesions and scar tissue has been shown to decrease pain and increase range of motion, but it has not been shown to increase strength.<sup>12,15,38,41,44,45</sup> When such smoothing procedures are performed, preservation of the integrity of the coracoacromial arch is critical in order to avoid the complication of anterosuperior escape. Because degeneration of the long head of the biceps tendon is frequently associated with cuff failure and may contribute to shoulder pain, surgical intervention may include biceps tenotomy (in which the tendon is cut) or tenodesis (in which the tendon is cut in the joint and secured to the humerus) along with the smoothing procedure.<sup>46</sup>

---

#### AREAS OF UNCERTAINTY

---

It is unclear why some persons with rotator-cuff failure are symptomatic, whereas others with seemingly identical patterns of failure are asymptomatic. The optimal management of chronic degenerative rotator-cuff lesions remains uncertain, including the approach to exercise programs and the role of complementary therapies. It is unclear when surgical intervention is warranted; a survey of 539 orthopedic surgeons showed remarkable inconsistency in perceptions about the indications for rotator-cuff surgery.<sup>47</sup> Randomized trials are needed to assess and compare nonsurgical with surgical interventions and to assess different surgical procedures for these conditions.

---

#### GUIDELINES

---

Professional guidelines have been published for the evaluation and management of shoulder conditions, including rotator-cuff lesions<sup>48</sup>; one guideline specifically addresses the imaging of rotator-cuff lesions.<sup>49</sup> The Washington State Department of Labor and Industries<sup>50</sup> and the New Zealand Group<sup>51</sup> have published official recommendations for the treatment of rotator-cuff conditions. These recommendations are consistent with the recommendations in this article.

---

#### CONCLUSIONS AND RECOMMENDATIONS

---

The diagnosis of rotator-cuff failure is suggested by a history of acute traumatic or progressive, insidious loss of shoulder strength, as described by the patient in the vignette. The physical examination of a shoulder with a rotator-cuff lesion should assess stiffness, pain on resisted motion, weakness, palpable tendon defects, crepitance, atrophy, and instability. Plain radiographs may help rule out other diagnoses that may underlie shoulder pain (e.g., degenerative arthritis of the glenohumeral joint) and may help determine the degree to which the humeral head is aligned with the glenoid. Ultrasonography or MRI is useful for evaluating the integrity of rotator-cuff tendons in patients when this information is needed to help guide treatment, but these imaging examinations may reveal tendon abnormalities even when the shoulder is asymptomatic. When an acute injury results in an abrupt loss of shoulder function, the evaluation of the rotator cuff should be expedited so that a traumatic rotator-cuff tear, if present, can be repaired before muscle and tendon atrophy occur.

With chronic cuff failure, such as in the patient in the vignette, I would recommend initially the use of mild analgesics and exercises to attempt to restore comfort, flexibility, and the strength of the shoulder muscles that remain intact. Exercises performed by the patient with or without the supervision of a therapist should be tried for 6 to 12 weeks to see whether they help. If pain, stiffness, and crepitance remain after the trial of nonsurgical management, I would discuss the potential risks, limitations, and benefits of surgery with the patient. If the patient continued to have bothersome symptoms, I would consider attempting a durable repair if there were minimal muscle atro-



phy and a sufficient quantity and quality of rotator-cuff tendon; if the patient was a poor candidate for repair, a smoothing procedure might be tried to reduce pain and improve range of motion.

No potential conflict of interest relevant to this article was reported.

An audio version of this article is available at [www.nejm.org](http://www.nejm.org).

#### REFERENCES

- Clark JM, Harryman DT II. Tendons, ligaments, and capsule of the rotator cuff: gross and microscopic anatomy. *J Bone Joint Surg Am* 1992;74:713-25.
- Oh LS, Wolf BR, Hall MP, Levy BA, Marx RG. Indications for rotator cuff repair: a systematic review. *Clin Orthop Relat Res* 2007;455:52-63.
- Ozaki J, Fujimoto S, Nakagawa Y, Masuhara K, Tamai S. Tears of the rotator cuff of the shoulder associated with pathological changes in the acromion: a study in cadavera. *J Bone Joint Surg Am* 1988;70:1224-30.
- Yamaguchi K, Ditsios K, Middleton WD, Hildebolt CF, Galatz LM, Teefey SA. The demographic and morphological features of rotator cuff disease: a comparison of asymptomatic and symptomatic shoulders. *J Bone Joint Surg Am* 2006;88:1699-704.
- Sher JS, Uribe JW, Posada A, Murphy BJ, Zlatkin MB. Abnormal findings on magnetic resonance images of asymptomatic shoulders. *J Bone Joint Surg Am* 1995;77:10-5.
- Milgrom C, Schaffler M, Gilbert S, van Holsbeeck M. Rotator-cuff changes in asymptomatic adults: the effect of age, hand dominance and gender. *J Bone Joint Surg Br* 1995;77:296-8.
- Zingg PO, Jost B, Sukthankar A, Buhler M, Pfirrmann CW, Gerber C. Clinical and structural outcomes of nonoperative management of massive rotator cuff tears. *J Bone Joint Surg Am* 2007;89:1928-34.
- Wendelboe AM, Hegmann KT, Gren LH, Alder SC, White GL Jr, Lyon JL. Associations between body-mass index and surgery for rotator cuff tendinitis. *J Bone Joint Surg Am* 2004;86:743-7.
- Wei AS, Callaci JJ, Juknelis D, et al. The effect of corticosteroid on collagen expression in injured rotator cuff tendon. *J Bone Joint Surg Am* 2006;88:1331-8.
- Wiggins ME, Fadale PD, Ehrlich MG, Walsh WR. Effects of local injection of corticosteroids on the healing of ligaments: a follow-up report. *J Bone Joint Surg Am* 1995;77:1682-91.
- Blair B, Rokito AS, Cuomo F, Jarolem K, Zuckerman JD. Efficacy of injections of corticosteroids for subacromial impingement syndrome. *J Bone Joint Surg Am* 1996;78:1685-9.
- Galatz LM, Silva MJ, Rothermich SY, Zaegel MA, Havlioglu N, Thomopoulos S. Nicotine delays tendon-to-bone healing in a rat shoulder model. *J Bone Joint Surg Am* 2006;88:2027-34.
- Duckworth DG, Smith KL, Campbell B, Matsen FA III. Self-assessment questionnaires document substantial variability in the clinical expression of rotator cuff tears. *J Shoulder Elbow Surg* 1999;8:330-3.
- Largacha M, Parsons IM IV, Campbell B, Titelman RM, Smith KL, Matsen F III. Deficits in shoulder function and general health associated with sixteen common shoulder diagnoses: a study of 2674 patients. *J Shoulder Elbow Surg* 2006;15:30-9.
- Zanetti M, Jost B, Hodler J, Gerber C. MR imaging after rotator cuff repair: full-thickness defects and bursitis-like subacromial abnormalities in asymptomatic subjects. *Skeletal Radiol* 2000;29:314-9.
- Matsen FA III, Boileau P, Walch G, Gerber C, Bicknell RT. The reverse total shoulder arthroplasty. *J Bone Joint Surg Am* 2007;89:660-7.
- Werner CM, Steinmann PA, Gilbert M, Gerber C. Treatment of painful pseudoparesis due to irreparable rotator cuff dysfunction with the Delta III reverse-ball-and-socket total shoulder prosthesis. *J Bone Joint Surg Am* 2005;87:1476-86.
- Teefey SA, Rubin DA, Middleton WD, Hildebolt CF, Leibold RA, Yamaguchi K. Detection and quantification of rotator cuff tears: comparison of ultrasonographic, magnetic resonance imaging, and arthroscopic findings in seventy-one consecutive cases. *J Bone Joint Surg Am* 2004;86:708-16.
- Iannotti JP, Ciccone J, Buss DD, et al. Accuracy of office-based ultrasonography of the shoulder for the diagnosis of rotator cuff tears. *J Bone Joint Surg Am* 2005;87:1305-11.
- Safran O, Derwin KA, Powell K, Iannotti JP. Changes in rotator cuff muscle volume, fat content, and passive mechanics after chronic detachment in a canine model. *J Bone Joint Surg Am* 2005;87:2662-70.
- Gerber C, Fuchs B, Hodler J. The results of repair of massive tears of the rotator cuff. *J Bone Joint Surg Am* 2000;82:505-15.
- Gladstone JN, Bishop JY, Lo IK, Flatow EL. Fatty infiltration and atrophy of the rotator cuff do not improve after rotator cuff repair and correlate with poor functional outcome. *Am J Sports Med* 2007;35:719-28.
- Ejnisman B, Andreoli CV, Soares BG, et al. Interventions for tears of the rotator cuff in adults. *Cochrane Database Syst Rev* 2004;1:CD002758.
- Norquist BM, Goldberg BA, Matsen FA III. Challenges in evaluating patients lost to follow-up in clinical studies of rotator cuff tears. *J Bone Joint Surg Am* 2000;82:838-42.
- Matsen FA, Lippitt SB, eds. *Shoulder surgery: principles and procedures*. Philadelphia: Saunders, 2004.
- McCallister WV, Parsons IM, Titelman RM, Matsen FA III. Open rotator cuff repair without acromioplasty. *J Bone Joint Surg Am* 2005;87:1278-83.
- Fuchs B, Gilbert MK, Hodler J, Gerber C. Clinical and structural results of open repair of an isolated one-tendon tear of the rotator cuff. *J Bone Joint Surg Am* 2006;88:309-16.
- Lafosse L, Brozka R, Toussaint B, Gobeze R. The outcome and structural integrity of arthroscopic rotator cuff repair with use of the double-row suture anchor technique. *J Bone Joint Surg Am* 2007;89:1533-41.
- Cofield RH, Parvizi J, Hoffmeyer PJ, Lanzer WL, Ilstrup DM, Rowland CM. Surgical repair of chronic rotator cuff tears: a prospective long-term study. *J Bone Joint Surg Am* 2001;83:71-7.
- Huijsmans PE, Pritchard MP, Berghs BM, van Rooyen KS, Wallace AL, de Beer JE. Arthroscopic rotator cuff repair with double-row fixation. *J Bone Joint Surg Am* 2007;89:1248-57.
- Galatz LM, Ball CM, Teefey SA, Middleton WD, Yamaguchi K. The outcome and repair integrity of completely arthroscopically repaired large and massive rotator cuff tears. *J Bone Joint Surg Am* 2004;86:219-24.
- Sugaya H, Maeda K, Matsuki K, Morishiki J. Repair integrity and functional outcome after arthroscopic double-row rotator cuff repair: a prospective outcome study. *J Bone Joint Surg Am* 2007;89:953-60.
- Coleman SH, Fealy S, Ehteshami JR, et al. Chronic rotator cuff injury and repair model in sheep. *J Bone Joint Surg Am* 2003;85:2391-402.
- Gerber C, Meyer DC, Schneeberger AG, Hoppeler H, von Rechenberg B. Effect of tendon release and delayed repair on the structure of the muscles of the rotator cuff: an experimental study in sheep. *J Bone Joint Surg Am* 2004;86:1973-82.
- Budoff JE, Nirschl RP, Guidi EJ. Debridement of partial-thickness tears of the rotator cuff without acromioplasty: long-term follow-up and review of the literature. *J Bone Joint Surg Am* 1998;80:733-48.
- Ainsworth R, Lewis JS. Exercise therapy for the conservative management of full thickness tears of the rotator cuff:

- a systematic review. *Br J Sports Med* 2007; 41:200-10.
37. Buchbinder R, Green S, Youd JM. Corticosteroid injections for shoulder pain. *Cochrane Database Syst Rev* 2003;1: CD004016.
38. Gazielly DF, Gleyze P, Montagnon C. Functional and anatomical results after rotator cuff repair. *Clin Orthop Relat Res* 1994;304:43-53.
39. Djurasovic M, Marra G, Arroyo JS, Pollock RG, Flatow EL, Bigliani LU. Revision rotator cuff repair: factors influencing results. *J Bone Joint Surg Am* 2001;83: 1849-55.
40. Matthews TJ, Hand GC, Rees JL, Athanasou NA, Carr AJ. Pathology of the torn rotator cuff tendon: reduction in potential for repair as tear size increases. *J Bone Joint Surg Br* 2006;88:489-95.
41. Harryman DT II, Mack LA, Wang KY, Jackins SE, Richardson ML, Matsen FA III. Repairs of the rotator cuff: correlation of functional results with integrity of the cuff. *J Bone Joint Surg Am* 1991;73: 982-9.
42. Green LB, Pietrobon R, Paxton E, Higgins LD, Fithian D. Sources of variation in readmission rates, length of stay, and operative time associated with rotator cuff surgery. *J Bone Joint Surg Am* 2003; 85:1784-9.
43. Jost B, Zumstein M, Pfirrmann CW, Gerber C. Long-term outcome after structural failure of rotator cuff repairs. *J Bone Joint Surg Am* 2006;88:472-9.
44. Lastayo PC, Wright T, Jaffe R, Hartzel J. Continuous passive motion after repair of the rotator cuff: a prospective outcome study. *J Bone Joint Surg Am* 1998;80: 1002-11.
45. Dines DM, Moynihan DP, Dines J, McCann P. Irreparable rotator cuff tears: what to do and when to do it: the surgeon's dilemma. *J Bone Joint Surg Am* 2006;88: 2294-302.
46. Boileau P, Baqué F, Valerio L, Ahrens P, Chuinard C, Trojani C. Isolated arthroscopic biceps tenotomy or tenodesis improves symptoms in patients with massive irreparable rotator cuff tears. *J Bone Joint Surg Am* 2007;89:747-57.
47. Dunn WR, Schackman BR, Walsh C, et al. Variation in orthopaedic surgeons' perceptions about the indications for rotator cuff surgery. *J Bone Joint Surg Am* 2005;87:1978-84.
48. Shoulder complaints. Elk Grove Village, IL: American College of Occupational and Environmental Medicine, 2004.
49. Steinbach L, Dalinka M, Daffner R, et al. Shoulder trauma. Reston, VA: American College of Radiology, 2005.
50. Criteria for shoulder surgery. Olympia, WA: Washington State Department of Labor and Industries, 2002.
51. The diagnosis and management of soft tissue shoulder injuries and related disorders. Wellington, New Zealand: New Zealand Guidelines Group, 2004.

Copyright © 2008 Massachusetts Medical Society.

**COLLECTIONS OF ARTICLES ON THE JOURNAL'S WEB SITE**

The *Journal's* Web site ([www.nejm.org](http://www.nejm.org)) sorts published articles into more than 50 distinct clinical collections, which can be used as convenient entry points to clinical content. In each collection, articles are cited in reverse chronological order, with the most recent first.