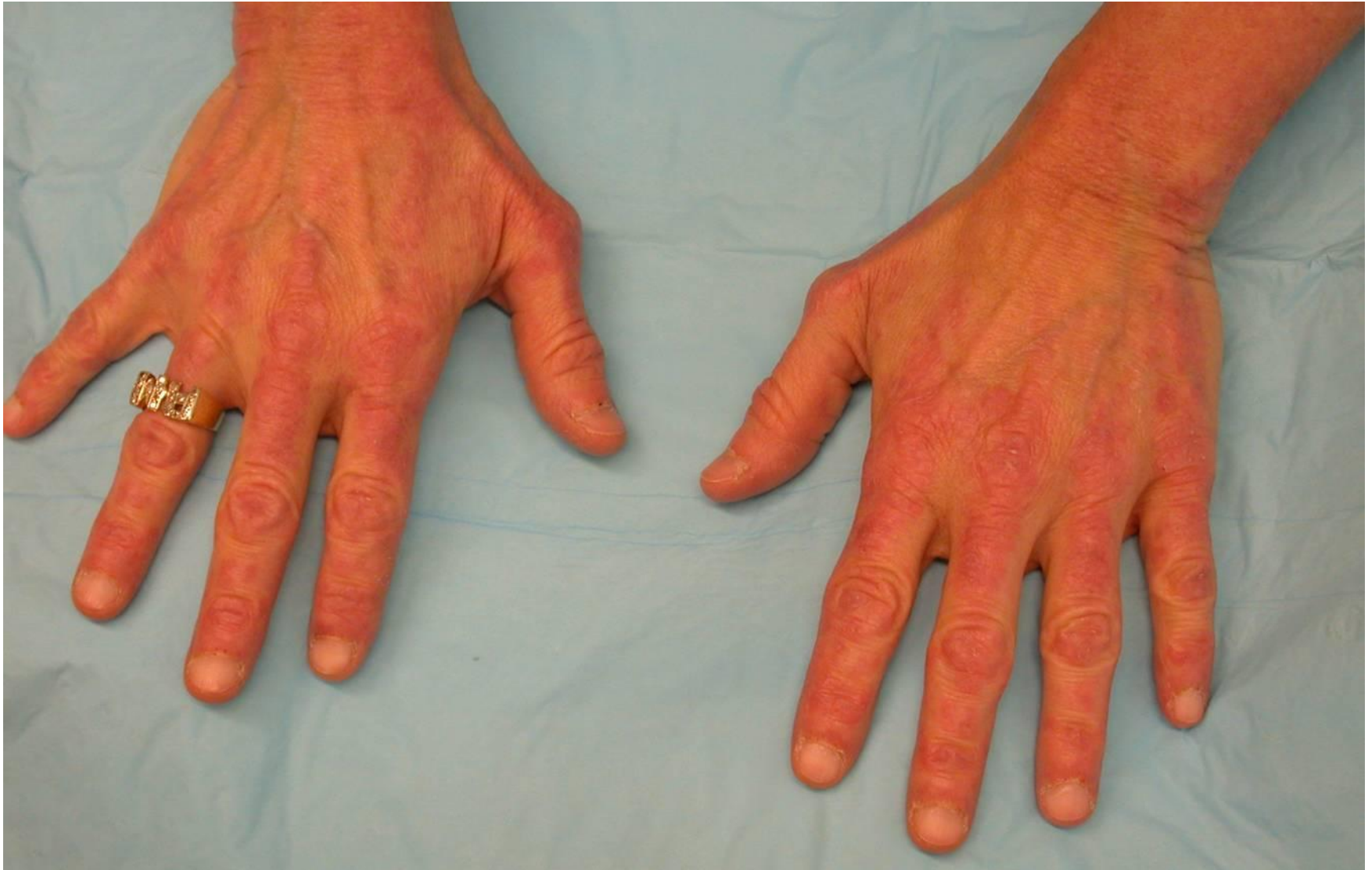
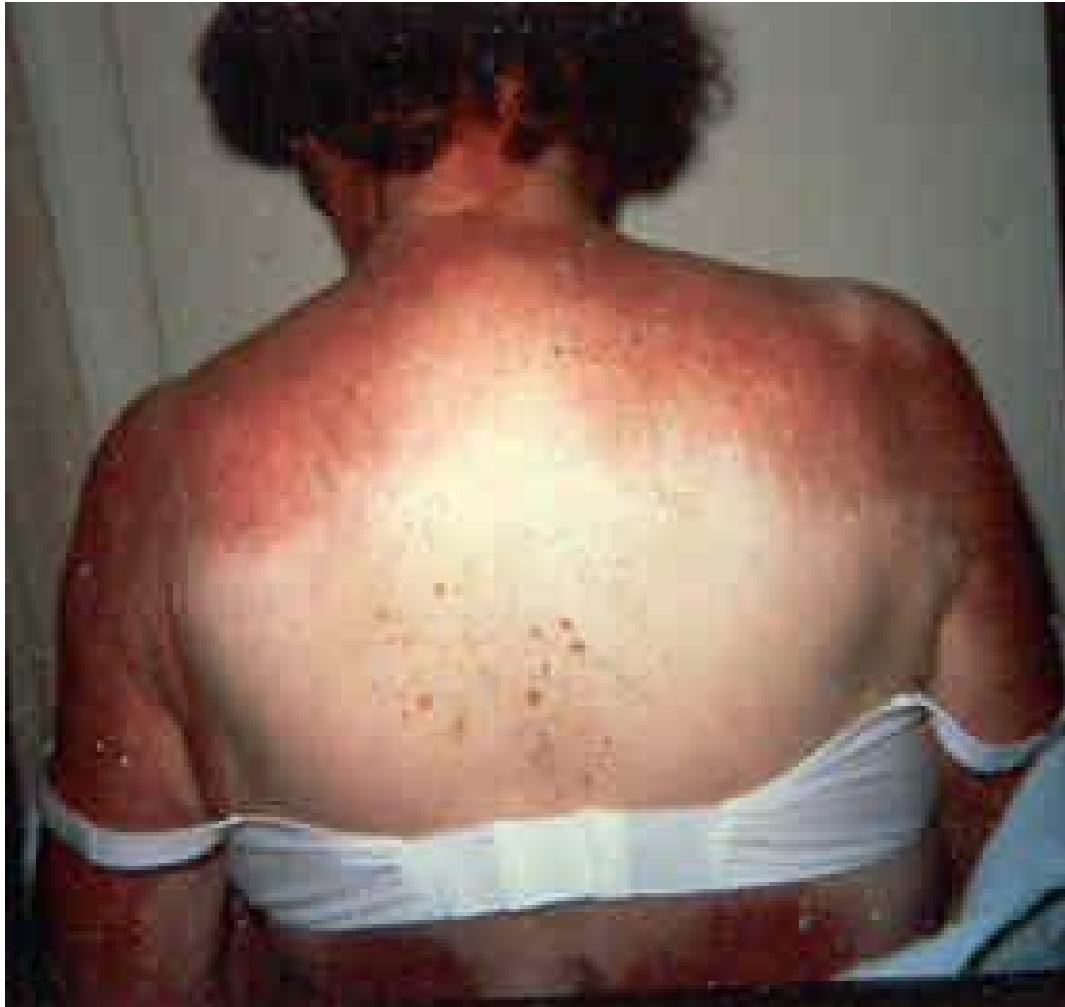



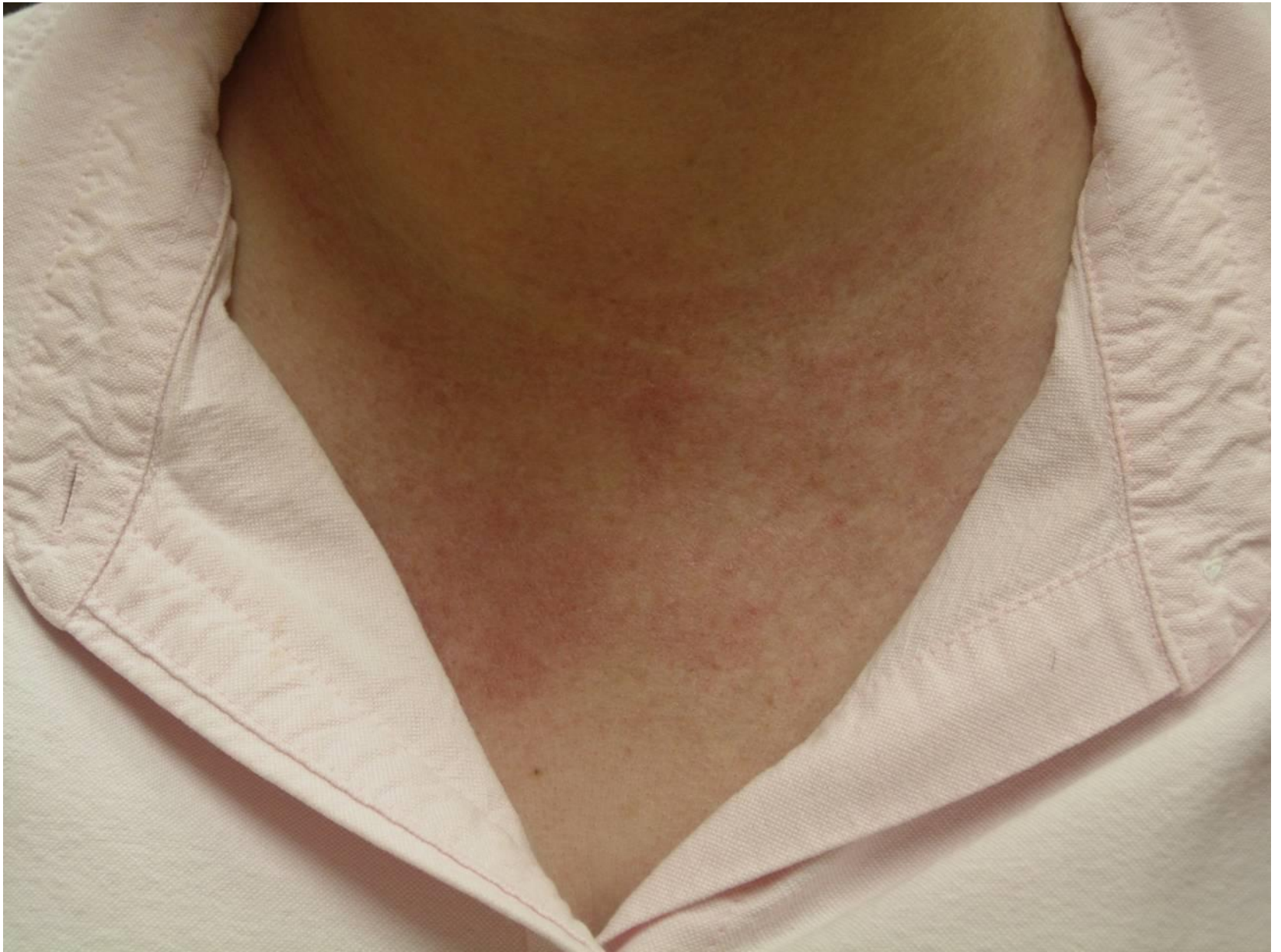7S. Linear extensor erythema- Erythema specifically located over the extensor tendon sheaths of the hands, forearms, feet and/or forelegs



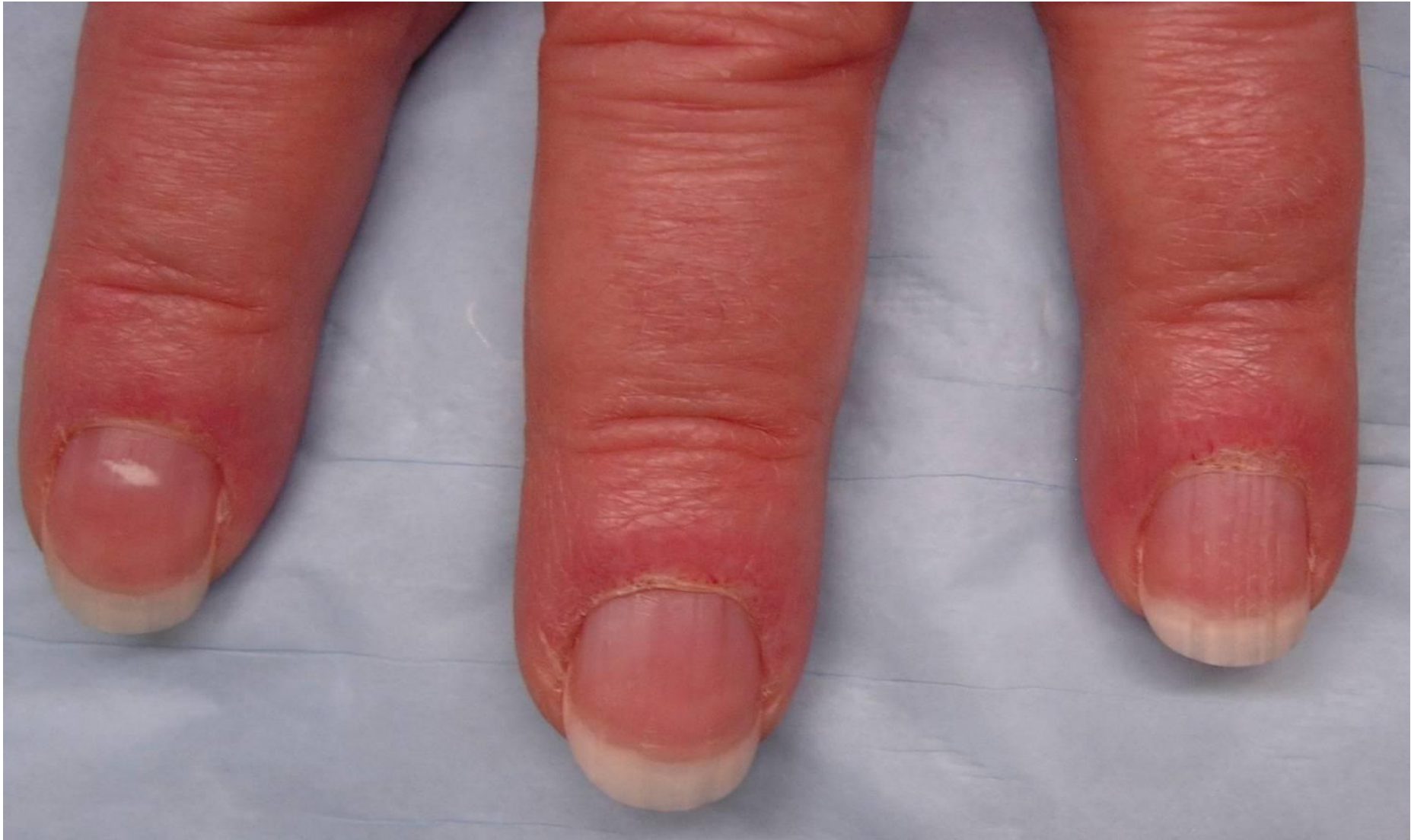7S. Linear extensor erythema- Erythema specifically located over the extensor tendon sheaths of the hands, forearms, feet and/or forelegs



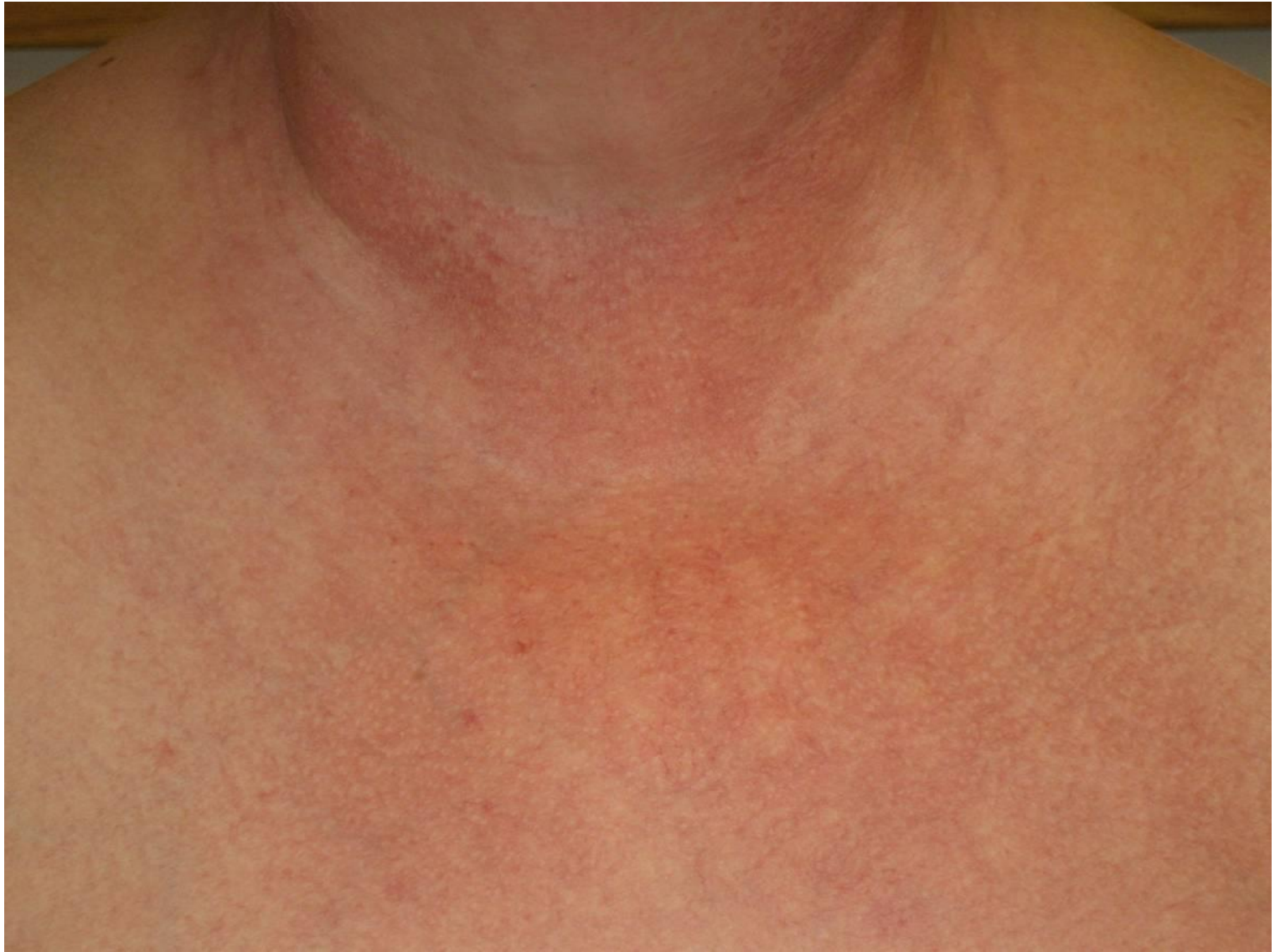5S. Shawl sign Confluent erythema around the posterior base of the neck, back and upper shoulders, often in the distribution of a shawl



4S. V neck. Confluent erythema around the anterior base of the neck and the upper chest, often in the shape of a “V”



13S. Cuticular dystrophy. Enlargement or overgrowth of the cuticle onto the nailbed



14S. Poikiloderma- A fine speckled pattern of hyperpigmented and hypopigmented macules interspersed with fine telangiectasia and cutaneous atrophy