

NIH RELAIS Document Delivery

NIH-10098619

NIH -- W1 NE204G

PAMELA GEHRON ROBEY
CSDB/NIDR/NIH Bldng 30 Rm 228
30 CONVENT DRIVE MSC 4320
BETHESDA, MD 20892

ATTN:	SUBMITTED:	2001-12-28 04:59:50
PHONE: 301-496-4563	PRINTED:	2001-12-28 11:33:36
FAX: 301-402-0824	REQUEST NO.:	NIH-10098619
E-MAIL:	SENT VIA:	LOAN DOC 5385325

NIH	Fiche to Paper	Journal
TITLE:	NEPHRON	
PUBLISHER/PLACE:	Karger. Basel, New York,	
VOLUME/ISSUE/PAGES:	1996;74(2):481-2	481-2
DATE:	1996	
AUTHOR OF ARTICLE:	Arik N; Biriken D; Akpolat T; Sungur C; Coskun C; Basoglu	
TITLE OF ARTICLE:	Severe hyperparathyroidism associated with fibrous	
ISSN:	0028-2766	
OTHER NOS/LETTERS:	Library reports holding volume or year 0331777 8893201	
SOURCE:	PubMed	
CALL NUMBER:	W1 NE204G	
REQUESTER INFO:	AB424	
DELIVERY:	E-mail: probey@DIR.NIDCR.NIH.GOV	
REPLY:	Mail:	

NOTICE: THIS MATERIAL MAY BE PROTECTED BY COPYRIGHT LAW (TITLE 17, U.S. CODE)

-----National-Institutes-of-Health,-Bethesda,-MD-----

Nurol Arık^a, Devrim Biriken^b
Tekin Akpolat^a, Cem Sungur^c
Candan Coşkun^a, Tarık Başoğlu^a
Mehtap Keskin^b, Murathan Şahin^a
Melahat Ögütçen Toller^b

Faculties of

^a Medicine and

^b Dentistry, Ondokuz Mayıs University, and

^c Bayındır Medical Center, Samsun, Turkey

Dear Sir,

Hyperparathyroidism (HPT) as a main etiologic factor of uremic bone disease may cause serious morbidity in uremic patients. On the other hand, fibrous dysplasia (FD) of bone is a disease of unknown etiology in which fibrous tissue replaces normal bone elements and its association with primary HPT has been rarely reported before [1]. In this report, we present a hemodialysis patient with severe HPT concomitant with craniofacial FD causing abnormal fascial deformity.

A 26-year-old woman was admitted to our hospital with a history of progressive difficulty in walking, widespread bone pain and abnormal enlargement of her face. Her history also revealed that she had been on regular hemodialysis therapy for 6 years because of renal failure of unknown etiology. Physical examination showed abnormal bilateral enlargement of the maxilla and mandible as well as multiple nodules palpable in the thyroidal region (fig. 1). Laboratory studies were as follows; serum calcium 7.6 mg/dl, serum phosphorus 6.3 mg/dl, alkaline phosphatase 1,560 U/l (normal 98-279), and parathyroid hormone (intact PTH) 1,749 ng/ml (normal 12-72). Bone roentgenograms disclosed extensive typical signs of HPT including widespread Brown tumor formation. Computerized tomography showed significant enlargement of all parathyroid glands as well as a well-trabeculated tumoral pattern in the maxilla and mandible. A whole-body bone scan was obtained following intravenous injection of 20 mCi ^{99m}Tc methylenediphosphonate. All scintigraphic features of renal osteostrophy including multiple nodules

Severe Hyperparathyroidism Associated with Fibrous Dysplasia: A Case Report

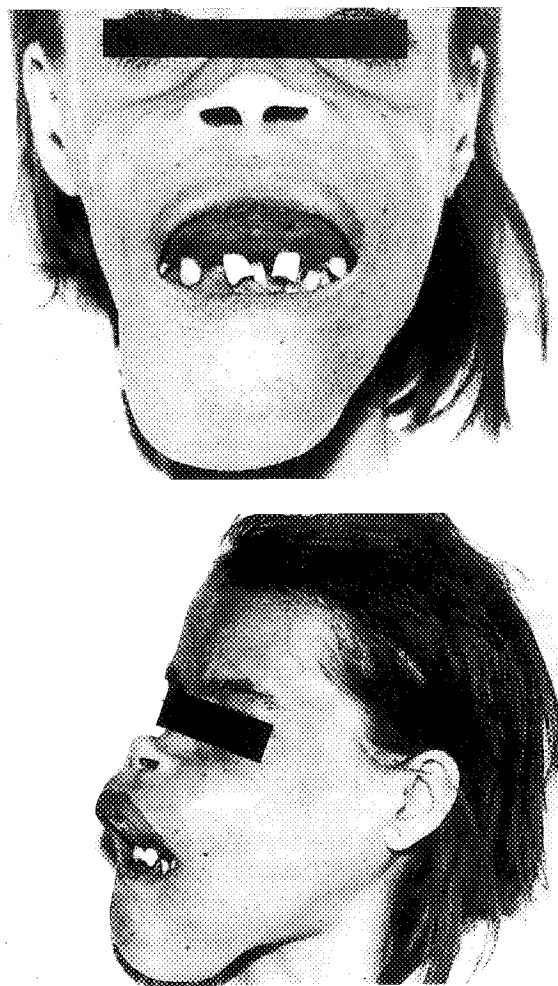


Fig. 1. Bilateral maxillary and mandibular enlargement.

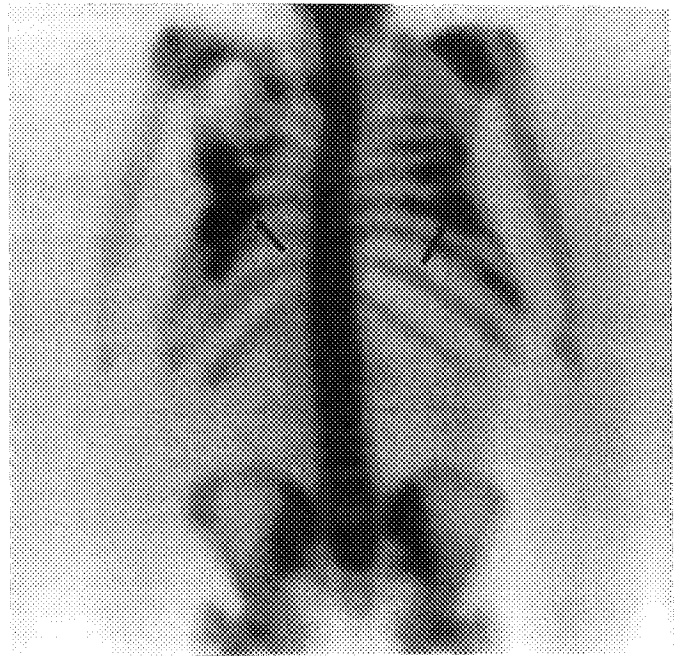
KARGER

E-Mail karger@karger.ch
Fax +41 61 306 12 34
http://www.karger.ch

© 1996 S. Karger AG, Basel
0028-2766/96/0742-0481\$10.00/0

Dr. Nurol Arık
Ondokuz Mayıs University
School of Medicine
Department of Nephrology
TR-55139 Kurupelit-Samsun (Turkey)

Fig. 2. The whole-body bone scan shows extensive skeletal involvement of severe hyperparathyroidism including Brown tumor formation in the ribs (arrows).



due to brown tumors in thoracic ribs, besides intense tracer uptake in maxilla and mandible, are shown in figure 2. Mandibular biopsy showed FD.

A history of long-term hemodialysis, the presence of hypocalcemia despite severe HPT and hyperplasia of all parathyroidal glands in radiologic investigations may be regarded as the significant diagnostic clues of secondary HPT in this case. But one cannot differentiate primary HPT due to hyperplasia of all parathyroidal glands from secondary HPT due to renal failure.

The well-known example of the association of FD and primary HPT is the McCune-Albright syndrome. This syndrome is characterized by precocious sexual development, fibrous dysplasia and many endocrinological abnormalities such as goiter, hyperthyroidism, HPT, acromegaly, Cushing's syndrome and hyperprolactinemia [2]. In the present case we could not detect any endocrinological abnormality except for HPT. As far as we know, except for the McCune-Albright syndrome, concomitance of HPT and FD had

been reported in 6 patients before with no acceptable theory to explain the association of these two clinical conditions and 1 of these patients had had the diagnosis of chronic renal failure [3].

FD and HPT are two main clinical conditions that should be considered in the differential diagnosis of facial skeletal abnormalities. The cystic form of FD may be confused with the radiologic signs of the facial involvement of HPT [2]. In the present case, the radiologic appearance does not show any cystic component, instead it forms a well-trabeculated pattern rather typical for FD. Besides, in view of the grotesque facial architecture commonly associated with FD, and the pathological diagnosis of FD, we thought FD as a possible diagnosis rather than HPT in this subject. But it must not be forgotten that both diseases may cause similar radiological and histological appearances in facial bones [4]. So, follow-up of the changes in her facial bone disease after parathyroidectomy is going to lead us to reach a clear-cut diagnosis.

References

- 1 Caudill R, Saltzman D, Gaum S, Granite E: Possible relationship of primary hyperparathyroidism and fibrous dysplasia: Report of a case. *J Oral Surg* 1977;35:483-490.
- 2 Mauras N, Blizzard RM: The McCune-Albright syndrome. *Acta Endocrinol* 1986;279:207-217.
- 3 Dierks EJ, Caudill RJ, O'Leary JD: Surgical recountering of a panfacial fibro-ossous deformity. *J Oral Surg* 1979;37:682-687.
- 4 Rosen IB, Palmer JA: Fibro-osseous tumors of the facial skeleton in association with primary hyperparathyroidism: An endocrine syndrome or coincidence? *Am J Surg* 1982;142:494-498.