



ELSEVIER

Available online at www.sciencedirect.com

SCIENCE @ DIRECT®

Veterinary Parasitology 116 (2003) 275–296

veterinary
parasitology

www.elsevier.com/locate/vetpar

Toxoplasma gondii, *Neospora caninum*, *Sarcocystis neurona*, and *Sarcocystis canis*-like infections in marine mammals

J.P. Dubey^{a,*}, R. Zarnke^b, N.J. Thomas^c, S.K. Wong^d,
W. Van Bonn^d, M. Briggs^e, J.W. Davis^f, R. Ewing^g,
M. Mense^h, O.C.H. Kwok^a, S. Romandⁱ, P. Thulliezⁱ

^a United States Department of Agriculture, Agricultural Research Service,
Animal and Natural Resources Institute, Animal Parasitic Diseases Laboratory,
BARC-East, Building 1001, 10300 Baltimore Avenue, Beltsville, MD 20705-2350, USA

^b Alaska Department of Fish and Game, 1300 College Road, Fairbanks, AK 99701-1599, USA

^c Department of the Interior, United States Geological Survey, National Wildlife Health Center,
6006 Schroeder Road, Madison, WI 53711, USA

^d United States Navy Marine Mammal Program, Biosciences Division, 53560 Hull Street Code 2351,
San Diego, CA 92101, USA

^e Brookfield Zoo, 3300 Golf Road, Brookfield, IL 60513, USA

^f U.S. Fish and Wildlife Service, Western Washington Fish and Wildlife Office,
510 Desmond Dr. SE Lacey, WA 98503, USA

^g Department of Commerce, NOAA Fisheries, 75 Virginia Beach Drive, Miami, FL 33149, USA

^h Department of Veterinary Pathology, Armed Forces Institute of Pathology,
Washington, DC 20306-6000, USA

ⁱ Laboratoire de la Toxoplasmose, Institut de Puériculture, 26 Boulevard Brune, F-75014, Paris, France

Received 25 May 2003; received in revised form 1 July 2003; accepted 13 July 2003

Abstract

Toxoplasma gondii, *Neospora caninum*, *Sarcocystis neurona*, and *S. canis* are related protozoans that can cause mortality in many species of domestic and wild animals. Recently, *T. gondii* and *S. neurona* were recognized to cause encephalitis in marine mammals. As yet, there is no report of natural exposure of *N. caninum* in marine mammals. In the present study, antibodies to *T. gondii* and *N. caninum* were assayed in sera of several species of marine mammals. For *T. gondii*, sera were diluted 1:25, 1:50, and 1:500 and assayed in the *T. gondii* modified agglutination test (MAT). Antibodies (MAT \geq 1:25) to *T. gondii* were found in 89 of 115 (77%) dead, and 18 of 30 (60%) apparently healthy sea otters (*Enhydra lutris*), 51 of 311 (16%) Pacific harbor seals (*Phoca vitulina*), 19 of 45 (42%) sea lions (*Zalophus californianus*), 5 of 32 (16%) ringed seals (*Phoca hispida*), 4 of

* Corresponding author. Tel.: +1-301-504-8128/8984; fax: +1-301-504-9222/6273.

E-mail address: jdubey@anri.barc.usda.gov (J.P. Dubey).

8 (50%) bearded seals (*Erignathus barbatus*), 1 of 9 (11.1%) spotted seals (*Phoca largha*), 138 of 141 (98%) Atlantic bottlenose dolphins (*Tursiops truncatus*), and 3 of 53 (6%) walruses (*Odobenus rosmarus*). For *N. caninum*, sera were diluted 1:40, 1:80, 1:160, and 1:320 and examined with the *Neospora* agglutination test (NAT) using mouse-derived tachyzoites. NAT antibodies were found in 3 of 53 (6%) walruses, 28 of 145 (19%) sea otters, 11 of 311 (3.5%) harbor seals, 1 of 27 (3.7%) sea lions, 4 of 32 (12.5%) ringed seals, 1 of 8 (12.5%) bearded seals, and 43 of 47 (91%) bottlenose dolphins. To our knowledge, this is the first report of *N. caninum* antibodies in any marine mammal, and the first report of *T. gondii* antibodies in walruses and in ringed, bearded, spotted, and ribbon seals. Current information on *T. gondii*-like and *Sarcocystis*-like infections in marine mammals is reviewed. New cases of clinical *S. canis* and *T. gondii* infections are also reported in sea lions, and *T. gondii* infection in an Antillean manatee (*Trichechus manatus manatus*).

© 2003 Elsevier B.V. All rights reserved.

Keywords: *Toxoplasma gondii*; *Neospora caninum*; *Sarcocystis neurona*; *Sarcocystis canis*; Antibodies; Agglutination tests; Sea otters; Walruses; Seals; Sea lion; Manatee

1. Introduction

Neospora caninum, *Toxoplasma gondii*, *Sarcocystis neurona*, and *S. canis* are related protozoans that cause mortality in many species of domestic and wild animals (Dubey and Beattie, 1988; Dubey and Lindsay, 1996; Dubey and Speer, 1991; Dubey et al., 2001a). Until the recent discovery of *T. gondii* as an important cause of encephalitis in sea otters (*Enhydra lutris*) (Thomas and Cole, 1996; Cole et al., 2000; Lindsay et al., 2000, 2001a; Miller et al., 2002a,b) there were rare reports of *T. gondii*-associated encephalitis in marine mammals (Table 1). In some of these reports listed in Table 1, it is uncertain whether *T. gondii* or related protozoa were the cause of disease. For example, a case of protozoal encephalitis (not listed in Table 1) in a Pacific harbor seal (*Phoca vitulina richardsi*) thought to be associated with *T. gondii* (Gulland et al., 1997) was recently found to be due to an unknown protozoa distinct from *T. gondii*, *N. caninum*, and *S. neurona* (Lapointe et al., 2003).

More is known of *T. gondii* infections in sea otters because the parasite has been isolated from tissues of many naturally exposed sea otters and the serologic status has been verified with bioassay data (Cole et al., 2000; Lindsay et al., 2001; Miller et al., 2002a,b). *T. gondii* was isolated from brains or hearts from 15 of 67 (22.3%) sea otters by Cole et al. (2000) and 24 of 75 (32%) by Miller et al. (2002b). Antibodies to *T. gondii* were reported in 56% of 223 sea otters (Miller et al., 2002a).

Toxoplasmosis has also been documented in Pacific harbor seals. Van Pelt and Dietrich (1973) first reported congenital toxoplasmosis in a 1-day-old seal and Miller et al. (2001b) isolated viable *T. gondii* from a diseased seal. Antibodies to *T. gondii* were found in 7.6% of 380 Pacific harbor seals by Lambourn et al. (2001).

Recently, *S. neurona* has been documented to cause encephalitis in Pacific harbor seals (Lapointe et al., 1998) and sea otters (Rosonke et al., 1999; Lindsay et al., 2000; Miller et al., 2001a), and concurrent infections with *T. gondii* and *S. neurona* have been found in a sea otter (Lindsay et al., 2001a), and a Pacific harbor seal (Miller et al., 2001b). As yet, there is no serologic survey for *S. neurona* or *N. caninum* infections in marine mammals.

Table 1
Summary of reports of clinical toxoplasmosis in sea mammals

Species	Source	Remarks	<i>T. gondii</i> demonstrated ^a					Reference
			Histo	TEM	Imm	Tach	Cyst	
Seals								
Elephant seal (<i>Mirounga angustirostris</i>)	Wild, California, USA	Encephalitis	Yes	ND	Yes	No	Yes	Dubey et al. (2003)
Northern fur seal (<i>Callorhinus ursinus</i>)	Wild, California, USA	Encephalitis	Yes	ND	Yes	Yes	Yes	Holshuh et al. (1985)
Pacific harbor seal (<i>Phoca vitulina richardsi</i>)	Wild, Cold Bay, AK, USA	1-day old, 11.5 kg, hepatitis	Yes	ND	ND	Yes	Yes	Van Pelt and Dietrich (1973)
Sea lion (<i>Zalophus californianus</i>)	Captive, zoo, Pennsylvania, USA	10-day old, disseminated	Yes	ND	ND	Yes	No	Ratcliffe and Worth (1951)
Dolphins								
Atlantic bottlenosed (<i>Tursiops truncatus</i>)	Captive, California, USA	Adult, myocarditis	Yes	ND	ND	Yes	Yes	Migaki et al. (1977)
	Wild, Florida, USA	One adult and her calf, disseminated	Yes	Yes	Yes	Yes	Yes	Inskeep et al. (1990)
	Wild, Florida, USA	Young male, hepatitis, adrenalitis	Yes	Yes	Yes	Yes	Yes	Cruickshank et al. (1990)
	Tuscany, Italy	Two wild, adult	Yes	ND	ND	Yes	No	Di Guardo et al. (1995a,b)
	Wild, USA	1 of 97 stranded adults	Yes	ND	ND	Yes ^b	Yes ^b	Schulman et al. (1997); present study
Striped (<i>Stenella coeruleoalba</i>)	Wild, Spain	Lymphadenitis, encephalitis, 4 of 110 stranded animals	Yes	ND	ND	Yes	No	Domingo et al. (1992)
	Wild, Tuscany, Italy	Four wild adults, encephalitis with co-infection with morbillivirus	Yes	ND	ND	Yes	No	Di Guardo et al. (1995a,b)
Indo-Pacific bottlenose (<i>Tursiops truncatus aduncus</i>)	Wild, Australia	Late term fetus, myocarditis, encephalitis	Yes	ND	Yes	Yes	Yes	Jardine and Dubey (2002)
Spinner (<i>Stenella longirostris</i>)	Wild, Hawaii, USA	Adrenalitis	Yes	Yes	ND	Yes	Yes	Migaki et al. (1977)
Risso's (<i>Grampus griseus</i>)	Wild, Spain	Adult and her fetus, disseminated	Yes	ND	Yes	Yes	Yes	Resendes et al. (2002b)
	Wild, Italy	One adult	Yes	ND	ND	Yes	No	Di Guardo et al. (1995a)
Tucuxi (<i>Sotalia fluviatilis guinensis</i>)	Wild, Rio de Janeiro, Brazil	1 Adult, lymphadenitis	Yes	ND	ND	Yes	Yes	Bandoli and de Oliveira (1977)
West Indian manatee (<i>Trichechus manatus</i>)	Wild, Florida, USA	Encephalitis	Yes	Yes	ND	No	Yes	Buergelt and Bonde (1983)
Beluga whale (<i>Delphinapterus leucas</i>)	Wild, Que., Canada	6-month old, encephalitis	Yes	ND	Yes	Yes	Yes	Mikaelian et al. (2000)
	Wild, Spain	31 years old, disseminated	Yes	ND	Yes	Yes	Yes	De Guise et al. (1995); Mikaelian et al. (2000)

^a Histo: histology, TEM: transmission electron microscopy, Imm: immunohistochemistry, Tach: tachyzoites, Cyst: tissue cysts, ND: no data.

^b The stage of the parasite was not specified.

N. caninum can cause encephalitis in dogs, cattle, sheep, goats, deer, and horses. In addition, serologic evidence of natural exposure has been found in several species of domestic and wild animals (Dubey, 2003). The primary objective of the present study was to determine the serum antibody prevalence of *N. caninum* and *T. gondii* in several species of marine mammals. We also review information on *T. gondii*, *S. neurona*, and *S. canis*-like infections in marine mammals because these reports are scattered among many not easily accessible scientific journals.

2. Materials and methods

2.1. Source of sera

2.1.1. Sea otters

2.1.1.1. Dead sea otters. Sea otters that died along the Pacific coast between 1992–2002 were submitted to the National Wildlife Health Center for necropsy. All California sea otters ($n = 100$) found in good postmortem condition were submitted from 1992–1996, and 25% of the fresh dead otters were submitted from 1997–2002. In addition, freshly dead sea otters ($n = 15$) found along the Washington coast were also examined (Table 2). Carcasses were

Table 2
Prevalence of *T. gondii* antibodies in marine mammals

Species	Source	No. tested	No. positive	% Positive (MAT \geq 1:25)	No. with MAT titers of		
					1:25	1:50	\geq 1:500
<i>Sea otters (Enhydra lutris)</i>							
Dead	California	100	82	82.0	10	32	40
	Washington	15	7	47.0	1	2	4
Live	Washington	30	18	60.0	0	3	15
Walruses (<i>Obobenus rosmarus</i>)	Alaska	53	3	5.6	2	1	0
Sea lions (<i>Zalophus californianus</i>)	Alaska	27	8	29.6	3	5	0
	California	18	11	61.1	3	6	2
Beluga whales (<i>Delphinapterus leucas</i>)	California	3	0	0	0	0	0
Harbor seals (<i>Phoca vitulina</i>)	Alaska	311	51	16.4	18	28	5
Ringed seal (<i>Phoca hispida</i>)	Alaska	32	5	15.6	2	3	0
Bearded seals (<i>Erignathus barbatus</i>)	Alaska	8	4	50.0	1	3	0
Spotted seals (<i>Phoca largha</i>)	Alaska	9	1	11.1	1	0	0
Ribbon seals (<i>Phoca fasciata</i>)	Alaska	14	0	0	0	0	0
Dolphins (<i>Tursiops truncatus</i>)	(A) California	94	91	96.8	9	76	6
	(B) ^a Florida	47	47	100	3	34	10

^a Wild population from Sarasota.

chilled or frozen, and shipped overnight to Madison, WI. Whole blood was collected from the heart at necropsy, centrifuged, serum separated, and stored at -80°C .

2.1.1.2. Live sea otters. Fifteen live, clinically normal sea otters were captured between Cape Alava and Destruction Island on Washington's outer coast from August 3–11, 2001. An additional 15 healthy sea otters were captured off the Washington coast in August 2002. Each otter was chemically immobilized while a blood sample was taken. Blood was centrifuged, serum separated, and stored at -80°C until analyses were conducted (Table 2).

2.1.2. Sea lions (*Zalophus californianus*), Atlantic bottlenose dolphins (*Tursiops truncatus*) and beluga whales (*Delphinapterus leucas*)

Serum samples were obtained from 16 January 1990 to 15 January 2002 from 94 dolphins (group A), 22 California sea lions, and three belugas at the U.S. Navy Marine Mammal Program (NMMP) in San Diego, CA.

Serum samples from 47 dolphins (group B) from Sarasota Bay, FL were obtained between June 1992 and June 2003. These dolphins belonged to the Sarasota Dolphin Project, where they conduct capture-release work with resident dolphins. The dolphins were from a few years to 24 years old, and both sexes were represented.

2.1.3. Alaskan marine mammals

Blood samples were collected from 311 Pacific harbor seals (*Phoca vitulina*), 53 walruses (*Odobenus rosmarus*), 32 ringed seals (*Phoca hispida*), 14 ribbon seals (*Phoca fasciata*), 27 sea lions (*Zalophus californianus*), nine spotted seals (*Phoca largha*) and eight bearded seals (*Erignathus barbatus*) in areas ranging from the coastal waters of Southeast Alaska to the Bering Strait from 1976 to 1998. Sera were separated and frozen until the time of testing.

2.2. Serologic testing for *T. gondii*

Sera were diluted 1:25, 1:50, and 1:500 and tested with the modified agglutination test (MAT) as described by Dubey and Desmots (1987). Sera from three sea lions from NMMP were diluted two-fold and titrated to an end point. In addition, sera from these animals were examined in parallel using formalin- and acetone-fixed antigens to differentiate between acute versus chronic IgG antibodies (Thulliez et al., 1986).

2.3. Serologic testing for *N. caninum*

Sera were diluted two-fold starting at a 1:40 dilution, and tested with the *N. caninum* agglutination test (NAT) as described by Romand et al. (1998).

2.4. Clinicopathologic examinations

2.4.1. Sea lions

In spring of 1993, three of four (Nos. 1–4) previously healthy NMMP California sea lions housed together in coastal, open-ocean waters in Charleston, South Carolina were

found to have swollen tonsils and raised, white cutaneous lesions located on the ventrum and inferior flippers. On April 26, 1993, a 9-year-old, castrated male sea lion (No. 1) was lethargic, anorexic, had a rectal temperature of 38.2 °C, and a heart rate of 100–120. After 2 days, the trainers reported a change in voice and swollen tonsils. Beginning 29 April, amoxicillin/clavulanate (5 mg/lb) was given twice daily for 5 days; prednisolone (20 mg) was also administered. The animal appeared to be gradually improving until May 3, when it became reluctant to swallow and ceased vocalizing. Hematologic examination on May 5 indicated a mild hypochloremia (98 mEq/l) (population mean \pm 1.5 S.D. = 106–112), low-serum iron (78 μ g/dl) (population mean \pm 1.5 S.D. = 81–175), mild-elevated transaminases (LDH 1053 U/l (population mean \pm 1.5 S.D. = 401–855), ALT 143 U/l (population mean \pm 1.5 S.D. = 23–73), and GGT 247 U/l (population mean \pm 1.5 S.D. = 25–111)), moderate hypergammaglobulinemia (6.0 g/dl) (population mean \pm 1.5 S.D. = 2.7–5.9), and lymphocytosis (1812 U/l) (population mean \pm 1.5 S.D. = 620–1800). Serum protein electrophoresis indicated that the hypergammaglobulinemia was due to a polyclonal gammopathy.

On May 4, two additional castrated male sea lions (Nos. 2 and 3) housed in the same open-ocean water pen were reluctant to swallow and were not vocalizing. Over the following 3 days (May 5–7), in addition to lethargy and anorexia, all three animals developed a rash localized mostly to the ventrum and/or the interior surface of the flippers; the rash involved raised, white skin lesions with an intermittent epidural collarette. At this time, all three animals had a mild-to-moderate lymphocytosis, and two had a thrombocytopenia. Amoxicillin/clavulanate treatment was reinitiated in sea lion No. 1 due to the severity of its clinical signs. The signs were milder in the other two animals, so they did not receive any antimicrobials. Sea lion No. 1 was unresponsive to antimicrobial treatment and supportive care, and its health continued to deteriorate until it died on May 16, 1993. Its tissues were fixed for histopathologic examination. The other two animals completely recovered within 30 days of illness onset.

The fourth sea lion (No. 4) housed with the above cases did not develop clinical signs. This animal had been deployed out of South Carolina on March 23 and did not rejoin the other three animals until 12 April.

In 1997, a captive 13-year-old dead female California sea lion (No. 5) in a private exhibit in Islamorada, FL was submitted to the University of Miami, School of Medicine for diagnosis.

A complete necropsy examination was performed on both sea lions. Samples of tissues were fixed in 10% buffered neutral formalin. Paraffin-embedded sections were cut at 5 μ m thickness and examined microscopically after staining with hematoxylin and eosin (H&E). Retrospectively, paraffin sections of tissues from both sea lions were submitted to the laboratory of the first author (JPD) for immunohistochemical staining with polyclonal rabbit antibodies against *T. gondii*, *N. caninum* and *S. neurona* as described (Lindsay and Dubey, 1989; Dubey and Hamir, 2000). A piece of formalin-fixed liver from sea lion No. 5 was processed for transmission electron microscopy.

2.4.2. Antillean manatee

Tissues from an adult Antillean manatee (*Trichechus manatus manatus*) were examined at necropsy by Dr. G.D. Bossart as part of a study on causes of mortality of manatees (Bossart, 1999).

This manatee had died many years ago in a fresh water reservoir in Georgetown, Guyana. No other information was recorded.

2.4.3. *Atlantic bottlenose dolphin*

During an investigation on the mortality of stranded dolphins, Schulman et al. (1997) recorded toxoplasmosis in 1 of 86 dolphins that had died in an epizootic of morbilli virus infection. No other details were provided. Histologic sections from this dolphin (AFIP case no. 2392939) were retrieved and reexamined. This dolphin of unknown sex and age was euthanized in 1988, and no other information was recorded. There were no unstained sections or paraffin blocks available for immunohistological examination.

3. Results

3.1. Serologic

Antibodies to *T. gondii* were found in all species of marine mammals tested except ribbon seals and beluga whales (Table 2).

The *T. gondii* antibody titer of the sea lion (No. 1) that died of histologically verified toxoplasmosis (see Section 3.2.1) was 1:51200, using both formalin and acetone-fixed *T. gondii* tachyzoites and the serum obtained on the day of death. The *T. gondii* antibody titer of sea lions No. 2 and 3 was 1:500. There was no serologic evidence of exposure (titer <1:25) to *T. gondii* in the fourth sea lion, using sera obtained in July and November 1993. The *T. gondii* titers of two other sea lions with higher titers (1:3200 and 1:25600) in formalin-fixed antigen were negative (<1:25) using the acetone-fixed antigen; the sera were obtained on July 13, 1993. These 4 animals are not included in Table 2.

N. caninum antibodies were found in 28 of 145 sea otters, 3 of 53 walruses, 1 of 27 sea lions, 11 of 311 harbor seals, 4 of 32 ringed seals, 1 of 8 bearded seals and 43 of 47 dolphins (Table 3). The *N. caninum* antibody titers of three walruses were 1:400, 1:200, and 1:200. Two of these animals were seronegative for *T. gondii* and one had a titer of 1:50.

3.2. Histologic

3.2.1. Sea lion

3.2.1.1. *T. gondii* infection. The main lesions were seen in the heart, liver, intestine, and lung of sea lion No.1. Lesions in the heart consisted of multiple small foci of inflammatory cells, primarily mononuclear cells in the myocardium, endocardium and epicardium with more severe reaction in endocardium (Fig. 1A). Numerous tachyzoites were present in the myocardial valves. These tachyzoites stained poorly with hematoxylin but were more easily recognized in sections stained by *Toxoplasma* antibody (Fig. 1B and C). In the large intestine, there was a diffuse mixed inflammatory infiltrate in the muscularis, submucosa, and lamina propria with occasional clusters of protozoa. In the liver, there was central congestion with multiple foci of necrosis and a mixed inflammatory filtrate in the sinusoids and periportal regions. Pigment-laden macrophages were frequent in the sinusoids but protozoa were

Table 3
Prevalence of *N. caninum* antibodies in sera of marine mammals

Species	Source	Tested	No. of positives	% Positive ($\geq 1:40$)	No. with MAT titers			
					1:40	1:80	1:160	1:320
Sea otters (<i>Enhydra lutris</i>) (dead)	California and Washington	115	17	14.8	7	6	2	2
Sea otters (live)	Washington	30	11	36.7	7	1	3	0
Walrus (<i>Obobenus rosmarus</i>)	Alaska	53	3	5.6	0	0	2	1
Sea lions (<i>Zalophus californianus</i>)	Alaska	27	1	3.7	1	0	0	0
Harbor seals (<i>Phoca vitulina</i>)	Alaska	331	11	3.5	7	3	0	1
Ringed seals (<i>Phoca hispida</i>)	Alaska	32	4	12.5	3	1	0	0
Bearded seals (<i>Erignathus barbatus</i>)	Alaska	8	1	0	1	0	0	0
Spotted seals (<i>Phoca largha</i>)	Alaska	9	0	0	0	0	0	0
Ribbon seals (<i>Phoca fasciata</i>)	Alaska	14	0	0	0	0	0	0
Dolphins (B) (<i>Tursiops truncatus</i>)	Florida	47	43	91.4	15	23	3	2

not visible. The pulmonic lesions consisted of interstitial pneumonia, subacute, diffuse, and with moderate type II pneumocyte hyperplasia. Only a few tachyzoites were seen in alveolar lumen. Protozoa stained positively with anti-*T. gondii*, but not with *S. neurona* and *N. caninum* antibodies.

3.2.1.2. *S. canis* infection. The liver of sea lion No. 5 had moderate random parenchymal inflammation and hepatocellular coagulative necrosis. The inflammatory cell infiltrate consisted of degenerative leukocytes, mainly neutrophils (Fig. 2A). There was also mild-multifocal portal fibrosis. Protozoa were seen within hepatocytes and among inflammatory cells. Immature schizonts with uninucleate (Fig. 2B) nucleus divided into many lobes (Fig. 2C), and mature schizonts were identified. Merozoites were formed internally or peripherally (Fig. 2D). Occasionally, an eosinophilic residual body was located centrally in schizonts (Fig. 2D). Free merozoites were approximately $5 \mu\text{m} \times 1 \mu\text{m}$ in size (Fig. 2E). The protozoa did not stain with anti-*T. gondii*, *N. caninum*, and *S. neurona* antibodies. Ultrastructurally, the protozoa were located directly in the cytoplasm of hepatocytes and macrophages without a parasitophorous vacuole. The merozoites contained a conoid, micronemes, but no rhoptries. The changes seen in lymph nodes, brain, lungs, kidneys and spleen were consistent with disseminated intravascular coagulopathy.

3.2.2. *T. gondii* infection in Antillean manatee

The main lesion was non-suppurative myocarditis characterized by multifocal areas of myocardial necrosis, and infiltration of mononuclear cells (Fig. 3A). Individual and groups of *T. gondii* tachyzoites were seen in lesions (Fig. 3B and C). Tissues were not available for further studies, but according to Bossart (personal communication to Ruth Ewing), the organisms had reacted to *T. gondii* polyclonal serum and were ultrastructurally consistent with the morphology of tachyzoites of *T. gondii*.

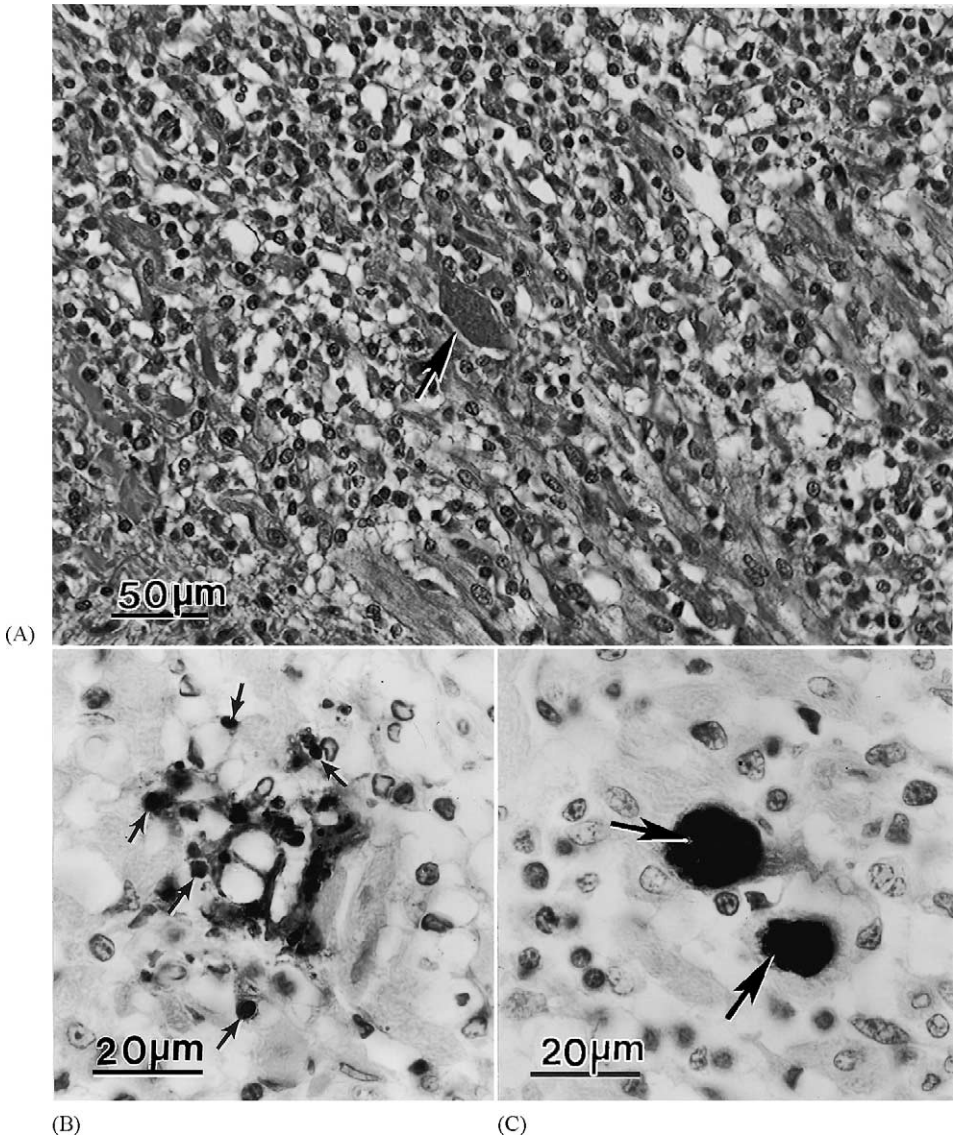


Fig. 1. Lesions and *T. gondii* tachyzoites in the myocardium of a sea lion (H&E). (A) Severe mononuclear cell infiltration and a group of *T. gondii* (arrow). (B) Focal necrosis and a group of individual tachyzoites (arrows). (C) Two groups (arrows) of organisms, not associated with lesion.

3.2.3. *T. gondii*-like infection in Atlantic bottlenose dolphin

Lesions associated with protozoal infection were confined to the adrenal glands. Randomly within the adrenal cortex and extending into the medulla, there were small areas of tissue architecture loss and replacement of normal cells by necrotic cells (Fig. 4). Few

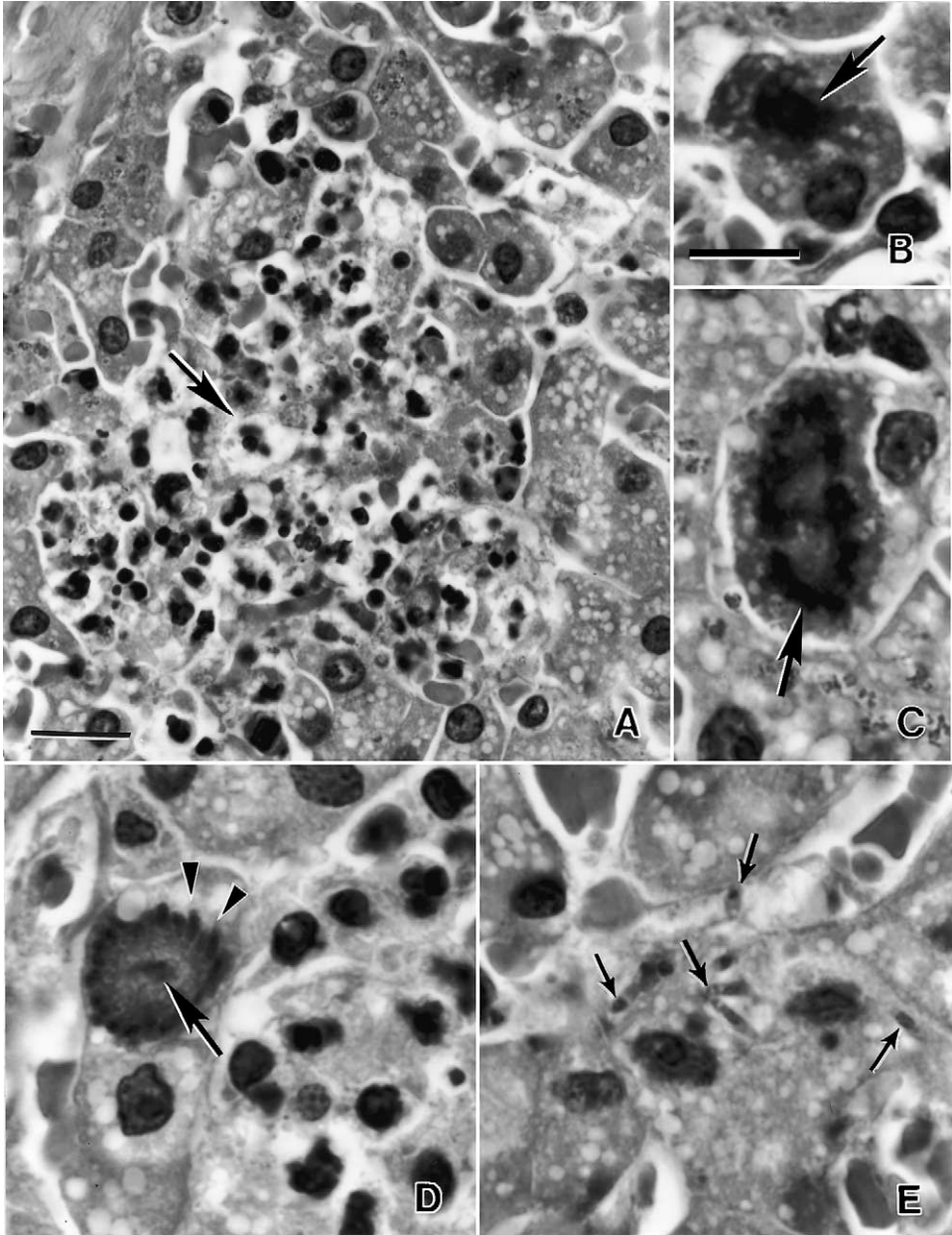


Fig. 2. *Sarcocystis canis*-associated hepatitis in a sea lion. (A) Focal necrosis (arrow). (B) Uninucleate (arrow) organism in a hepatocyte. (C) Schizont with a multilobed nucleus (arrow), all nuclear lobes are connected. (D) Schizont with merozoites (arrowheads) budding at the periphery. (E) Individual merozoites (arrows) (H&E; bar in A = 20 μ m, bar in B–E = 10 μ m).

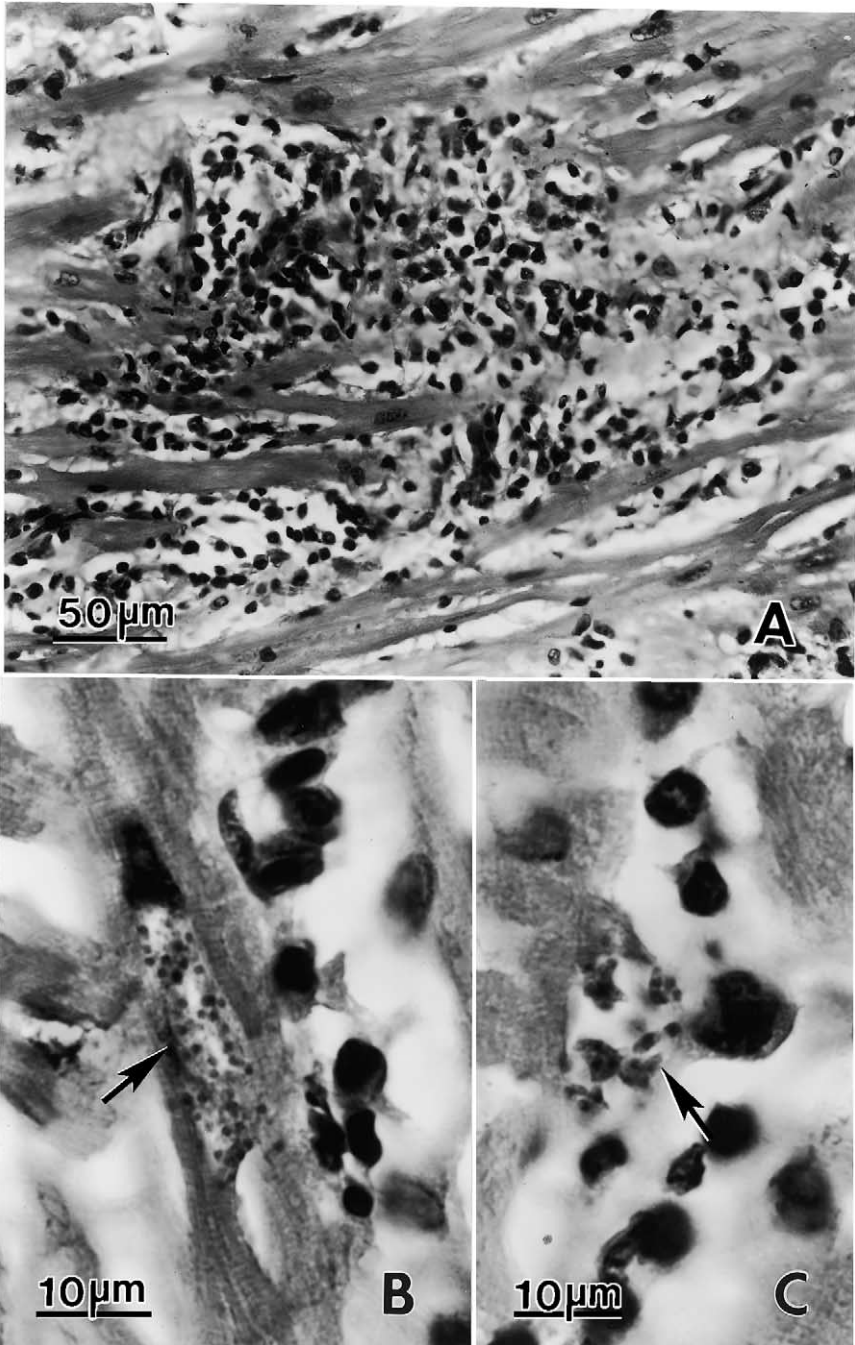


Fig. 3. Lesions and *T. gondii* tachyzoites in the myocardium of an Antillean manatee (H&E). (A) Mononuclear cell infiltration. (B, C) Groups of tachyzoites (arrows).

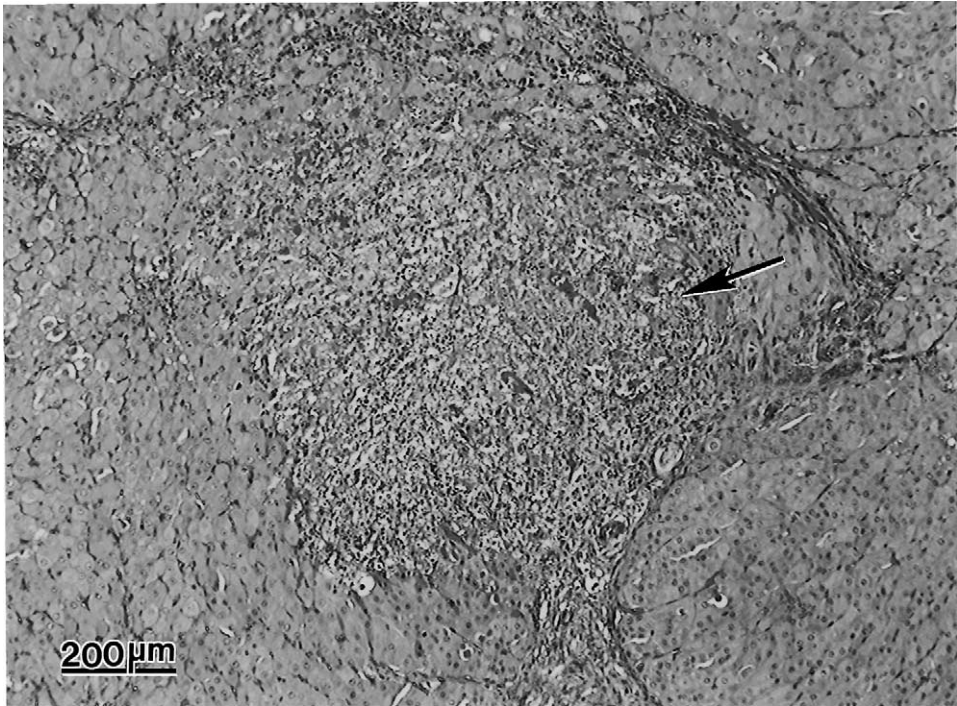


Fig. 4. Focus of necrosis and inflammation (arrow) in the adrenal of a dolphin (AFIP case 2392939)(H&E).

surrounding cells had pyknotic or karyolytic nuclei and loss of cellular detail. Admixed with, and often times peripheral to these foci were varying numbers of histiocytes, neutrophils and lymphocytes, necrotic cellular debris, hemorrhage, and edema fluid. Occasionally, usually on the periphery of the areas of inflammation and necrosis, but also in areas free of inflammation, there were numerous protozoal groups measuring $30\ \mu\text{m} \times 15\ \mu\text{m}$ in diameter, and containing numerous elongated zoites (Fig. 5A and B). The tissue cyst wall was not clear and some groups stained too intensely to discern structural details (Fig. 5B). Also associated with the areas of inflammation were abundant free elongated tachyzoites, which stained darkly eosinophilic and contained a centrally located basophilic nucleus. Sections of paraffin embedded tissue or formalin-fixed archival tissue was not available for additional light microscopic interpretation or confirmation of the diagnosis.

4. Discussion and review of protozoal encephalitis in marine mammals

4.1. *T. gondii* infections

4.1.1. Serology

In the present study, *T. gondii* antibodies were found in 77% of dead and 60% of live sea otters. This seroprevalence rate is much higher than reported previously. Miller et al.

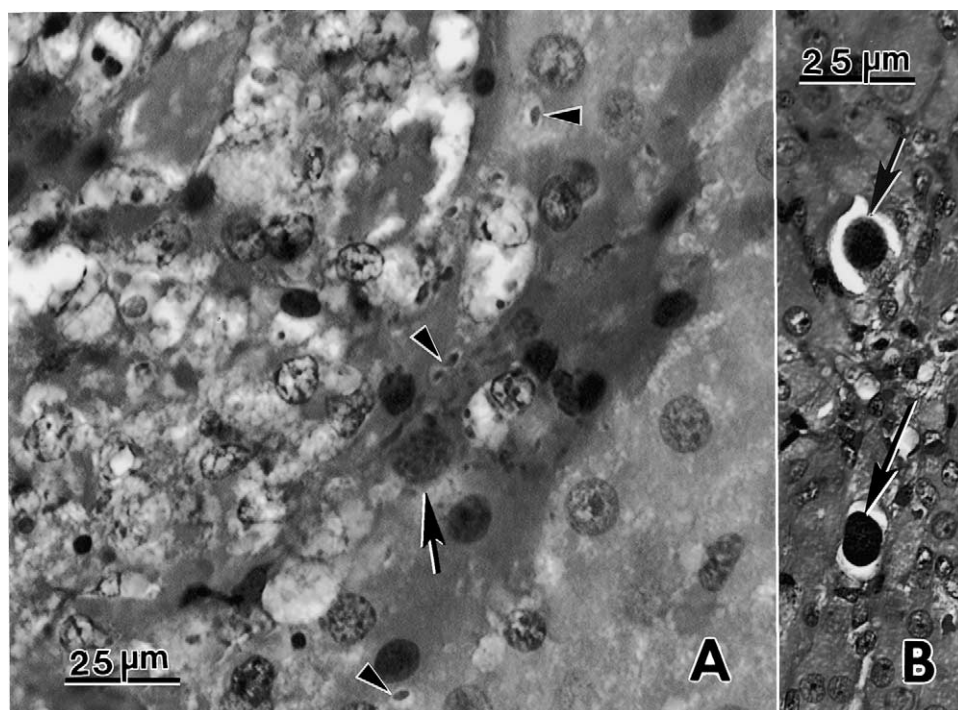


Fig. 5. *T. gondii*-like organisms in the adrenal of the dolphin shown in Fig. 4. (A) Note several individual tachyzoites (arrowheads) and a faintly stained group (arrow). (B) Two darkly stained tissue cyst-like groups (arrows) (H&E).

(2002a,b) reported *T. gondii* antibodies in 42% of 116 live and 62% of 107 dead sea otters in one study (Miller et al., 2002a). In another study they found *T. gondii* antibodies in 61% of 77 dead and 36% of 80 live sea otters from California, 38% of 21 live sea otters from Washington and 0% of 65 sea otters from Alaska (Miller et al., 2002b). These differences may be related in part to different serologic tests, threshold values, and source of sea otters used. Therefore, it is necessary to discuss methods surveyed. Miller et al. (2002a,b) used an indirect fluorescent antibody test (IFAT) at a threshold value of 1:320 to determine *T. gondii* antibodies in sea otters. Miller et al. (2002b) evaluated the diagnostic efficiency of IFAT for the diagnosis of *T. gondii* infection in 77 dead sea otters by comparing serology and demonstration of the parasite in tissues by immunohistochemistry and by isolation of the parasite in cell culture. *T. gondii* was demonstrable in 20 of 27 sea otters with IFAT titers of 1:320 or higher, in one of five animals with a titer of 1:160, and in none of the 24 sea otters with an IFAT titer of <1:80. Thus, they conservatively chose a diagnostic titer of 1:320 for IFAT.

One disadvantage of the IFAT is that its specificity depends on the species-specific conjugate needed in the test, for which Miller et al. (2002a) used anti-ferret conjugate. In the present study, a direct modified agglutination test (MAT) was used instead of IFAT. The MAT is simple to perform, the antigen is stable for months at 4 °C, and the test works

for all species of mammals and birds infected with *T. gondii*. Although the specificity and sensitivity of MAT have not been evaluated for the diagnosis of toxoplasmosis in marine mammals, it is the most evaluated and specific test for the diagnosis of toxoplasmosis in animals, particularly pigs (Dubey et al., 1995, 2002; Dubey, 1997). The threshold value of 1:25 used for MAT is based on experience with thousands of sera from many naturally- and experimentally infected species of animals (J. P. Dubey, unpublished). In our opinion, a 1:25 titer in the MAT is specific for *T. gondii*, although, *T. gondii* has been isolated occasionally from animals with MAT titers lower than 1:25 (Dubey et al., 1995, 2002). Hemolysis of sera is not a major problem for detection of *T. gondii* antibodies with MAT using a 1:25 dilution of serum and using the mouse-derived tachyzoites, contrary to the experience of Miller et al. (2002b). Unfortunately, the only known cases of seropositivity by MAT and demonstration of *T. gondii* in a naturally infected marine animal is in a whale that had a low-MAT titer of 1:25 and had demonstrable *T. gondii* in tissues (Mikaelian et al., 2000, see Table 1) and the sea lion in the present study.

For serologic surveys even lower titers should not be ignored unless the serologic tests have been extensively evaluated. Although the study by Miller et al. (2002b) is commendable, cell cultures and immunohistochemistry are very insensitive methods to detect low levels of *T. gondii* infections in subclinically infected animals. Less than 5 g of total brain tissue was used for their study. The lack of isolation of *T. gondii* from 14 attempts using untrypsinized brain (Miller et al., 2002b) indicates that *T. gondii* is unevenly distributed in brain tissue of sea otters. One should also take into consideration that the sea otters selected for isolation were dead and possibly diseased. Therefore they may have a higher concentration of parasites than in apparently healthy but infected animals. For example, in naturally exposed pigs, the density of *T. gondii* may be as low as 1 tissue cyst in 100 g of tissue, which is not likely to be detected by histology, by bioassay in mice, or by cell culture. In one study, hearts of 1000 naturally exposed pigs were bioassayed in 10,000 mice and 183 hearts were bioassayed additionally in cats. *T. gondii* was not detectable by bioassay in mice inoculated with a pepsin-digest of 100 g of hearts from each of 62 pigs that were shown to be infected by bioassay in cats (Dubey et al., 1995). Bioassay in mice is much more sensitive than detection by bioassay in cell culture for isolation of *T. gondii* (Abbas, 1967).

In the present study, antibodies to *T. gondii* were found in ringed, bearded, spotted and ribbon seals, and walrus for the first time. As mentioned earlier, MAT *T. gondii* antibodies had been previously reported in 7.6% of 38 Pacific harbor seals (Lambourn et al., 2001). Additionally, there were reports of *T. gondii* antibodies in four other marine mammals. Di Guardo et al. (1995b) reported IgG antibodies in a striped dolphin and a Risso's dolphin from Italy. Riemann et al. (1974) found an indirect hemagglutination test titer of 1:64 in a captive sea lion in USA. Mikaelian et al. (2000) reported MAT *T. gondii* antibodies in 6 of 27 beluga whales from Canada.

4.1.2. *Clinical toxoplasmosis*

4.1.2.1. Sea lions. In the present study, we report the death of an adult NMMP California sea lion from *T. gondii* infection. In sea lion No. 1, diagnosis was confirmed immunohistochemically as well as by serologic examination. This animal had a very high antibody

titer in both formalin- and acetone-fixed antigens indicative of acute infection. Two other animals housed with this sea lion developed only low antibody titers. While all three sea lions developed similar clinical signs within a short time period, conclusive diagnosis was made only in the animals that died. As paired serum samples were not submitted on the same day, active infection could not be confirmed or ruled out via serum antibody titers. As such, another primary etiology (e.g. a viral infection), leading to immunosuppression and reactivation of a latent *T. gondii* infection in the animals that died, cannot be ruled out. If this was a common source outbreak of toxoplasmosis in the sea lions, exposure to *T. gondii* was more likely to have occurred in the environment. At NMMP all animals are fed controlled, fresh frozen, thawed fish, decreasing the likelihood of foodborne exposure. Animals are housed, however, in open-ocean, coastal water enclosures, and it is not uncommon to find stray cats along the coastline.

There are two previous reports of fatal generalized toxoplasmosis in sea lions kept in captivity. The first case was a 10-day-old animal (Ratcliffe and Worth, 1951) born in a Philadelphia zoo and the other was an adult kept for thermoregulation studies. Both of these previous cases would have had ample opportunities to be infected with *T. gondii* oocysts shed by cats in their immediate environment. Moreover, the adult sea lion had been kept in a fresh water pool.

4.1.2.2. Seals. Seals are related to sea lions and both are pinnipeds. Van Pelt and Dietrich (1973) described toxoplasmosis-like hepatitis in a newborn seal (1-h old). The animal also had concurrent staphylococcal septicemia. Numerous protozoa, considered to be *T. gondii* tachyzoites and tissue cysts were present in hepatic lesions. The diagnosis was based solely on examination of sections stained with hematoxylin and eosin. In the opinion of the primary author, this case resembles the *S. canis*-like hepatitis (see Section 4.4).

Holshuh et al. (1985) reported disseminated toxoplasmosis in an 18-year-old fur seal found stranded on a California coast. The animal died 1 month after capture. Diagnosis was confirmed immunohistochemically. In retrospect, it is uncertain if the animal was infected before capture or became infected in captivity.

Gulland et al. (1997) mentioned a case of toxoplasmosis in a Pacific harbor seal. From 1990–1995, 700 live seal pups were stranded on a California coast and transported to a Marine Mammal Center where 379 died after various times in captivity. Of these, 162 animals were studied histologically. Of those examined, 74 had lesions in adrenal glands suggestive of herpes virus infection, and all of them had marked lymphoid atrophy in thymus, spleen, and lymph nodes. Among these 74 animals was a case of protozoal meningoencephalitis. Based on detailed serologic and immunohistologic investigation, this case was not due to *T. gondii* (Lapointe et al., 2003). The parasite in this seal did not react with *T. gondii*, *N. caninum*, and *S. neurona* antibodies. The seal had no *T. gondii* antibodies, and the parasite was structurally distinct from any known apicomplexan (for details, see Lapointe et al., 2003).

4.1.2.3. Dolphins. All cases of *T. gondii*-like illness summarized in Table 1 were in free-range stranded dolphins except the case reported in Jardine and Dubey (2002). In all cases, toxoplasmosis occurred in young animals or in those animals considered to be in an immunosuppressed state. There are four reports of toxoplasmosis in newborns and

their mothers. Inskip et al. (1990) described disseminated toxoplasmosis in a stranded *T. truncatus* and her calf. Both animals died within 36 h of capture. The age of the calf was unknown but the animal was considered to be nursing. Lactation is known to aggravate latent toxoplasmosis (Dubey and Beattie, 1988), and may have accounted for more severe lesions in the mother. Cruickshank et al. (1990) described generalized toxoplasmosis in an immature dolphin. Both dolphins reported by Inskip et al. (1990) had lesions and numerous *T. gondii* in adrenal glands suggesting immunosuppression probably due to morbillivirus infection.

Jardine and Dubey (2002) reported the first case of confirmed congenital toxoplasmosis in a dead fetus born to a captive dolphin that became infected in captivity. Resendes et al. (2002b) documented generalized toxoplasmosis in a dolphin and her fetus; no cause for immunosuppression was found.

Toxoplasmosis was diagnosed in 7 of 62 cetaceans stranded off the coast in Italy (Di Guardo et al., 1995a,b), 4 of 58 dolphins in Spain (Domingo et al., 1992), and 1 of 742 dolphins in USA (Schulman et al., 1997); all of these cases are considered to be in animals suffering from morbillivirus infection. Therefore, prevalence of clinical *T. gondii* infection in normal dolphin population is unknown. Reidarson et al. (1998) found a *T. gondii*-like organism in 1 of 18 common dolphins (*Delphinus delphis*) stranded on the California coast. A single tissue cyst measuring 160 μm in diameter and containing many 2–3 $\mu\text{m} \times 1 \mu\text{m}$ organisms was thought to be *T. gondii*. However, in the opinion of the primary author, the tissue cyst was too large to be *T. gondii*. Tissue cysts of *T. gondii* in histologic sections of brain are smaller than 70 μm in diameter (Dubey and Beattie, 1988). We were unable to trace material from this dolphin in records of AFIP to verify diagnosis.

The parasite in the Atlantic bottlenose dolphin that Schulman et al. (1997) reported and restudied in the present report resembled *T. gondii* but diagnosis could not be confirmed because no sections were available for immunohistochemistry. The tissue cyst-like structures seen in this animal were not typical of *T. gondii*.

4.1.2.4. Sea otters. Southern sea otters of California are listed as a threatened species under the Endangered Species Act in the United States. There are at least three distinct geographically separated, established “colonies” off the coasts of California, Washington, and Alaska with minimal, if any, intermixing among groups (Miller et al., 2002b). The role of *T. gondii* as the primary cause of mortality in sea otters has not been established but is under investigation (Thomas and Cole, 1996; Cole et al., 2000; Miller et al., 2002b). Cole et al. (2000) isolated *T. gondii* from 15 of 67 selected sea otters. Two of these animals had severe encephalitis suggesting *T. gondii* was the cause of illness. In the remaining 13 animals proven to be infected with *T. gondii*, lesions were mild and may not have been the cause of death. Lindsay et al. (2001a) described toxoplasmic encephalitis in a sea otter from Washington state with *T. gondii* demonstrated in lesions, but this animal also had a concurrent infection with *S. neurona* and the lesions associated with *S. neurona* were more extensive than those associated with *T. gondii* (Lindsay et al., 2001a). Miller et al. (2002b) isolated *T. gondii* from the brains of 24 sea otters and detected it immunohistochemically in 13 out of 77 selected dead sea otters in California. The protozoa that reacted with *T. gondii* antibodies did not react with *S. neurona* antibodies but it is unclear if these animals were not concurrently infected with *S. neurona* (Miller et al., 2002b). Although Miller et al. (2002b)

identified *T. gondii* immunohistochemically in 13 of 77 dead sea otters, it was not stated if *T. gondii* was responsible for encephalitis. Thus, there is little information at present concerning the role of *T. gondii* as a cause of mortality in sea otters.

4.1.2.5. Whales. Of three beluga whales included in the present study, none had antibodies to *T. gondii*. As stated in [Table 1](#), toxoplasmosis was diagnosed in two beluga whales from the St. Lawrence Estuary, Que., Canada. In both cases, evidence for morbilli virus or other infections was not found ([Mikaelian et al., 2000](#)).

4.1.2.6. Manatees. Manatees are large marine mammals that prefer warm waters. *T. gondii* tissue cysts were found in sections of brain of an animal that had mild lesions in the brain ([Buergelt and Bonde, 1983](#)). It is uncertain if *T. gondii* was the cause of death because tachyzoites were not seen.

The case reported in the present study differs from the case reported by [Buergelt and Bonde \(1983\)](#) who found only tissue cysts, probably an incidental finding, whereas in the present animal *T. gondii* was the cause of the myocarditis. In addition, the present case was from an Antillean manatee from the Caribbean whereas the previously published case was in a West Indian manatee from Florida.

4.1.3. Sources of *T. gondii* infection in marine mammals

The ingestion of oocysts in contaminated food or water and the ingestion of *T. gondii*-infected tissues are the two main sources of postnatal *T. gondii* infection. The mechanism of *T. gondii* infection in marine mammals is most intriguing because most feed on fish or invertebrates, cold-blooded animals, or they are exclusively herbivorous, thus ingestion of *T. gondii*-infected meat is unlikely. Felids are the only known hosts that can excrete environmentally resistant oocysts. Cats can excrete millions of oocysts, and there are >100 million cats in the United States. [Miller et al. \(2002a\)](#) presented evidence that land-based surface runoff was of significant risk for *T. gondii* infection in sea otters, so it is possible that *T. gondii* oocysts could be washed into the sea via runoff contaminated by cat excrement. The role of marine invertebrates in the life cycle of *T. gondii* is unknown. *T. gondii* oocysts are extremely resistant to environmental influences and therefore likely to survive in the sea. Although *T. gondii* oocysts were mentioned by [Thomas and Cole \(1996\)](#) to have sporulated in seawater, there is a need to study the survival of *T. gondii* oocysts in seawater and marine invertebrates. *T. gondii* does not parasitize any cold-blooded animals. However, mollusks can filter large quantities of water and may thus concentrate microbes from the water. Experimentally, *T. gondii* oocysts have been concentrated by mollusks ([Lindsay et al., 2001b](#)). Sea otters feed on a variety of invertebrates and may thus become infected if oocysts were concentrated by these transport hosts. Indian manatees are completely herbivores and feed on aquatic plants. [Buergelt and Bonde \(1983\)](#) suggested that the Indian manatee might have become infected by ingesting oocysts washed in with sewage because manatees are warm-water animals and they inhabit coastal areas that are highly urbanized; however, walrus are cold-water animals that live away from urban areas.

T. gondii infection of dolphins is even more intriguing because they drink little or no water and their nutritional requirements are derived from fish, squid, or other cold-

blooded sea animals they consume. The finding of *T. gondii* antibodies in 100% of the wild Atlantic bottlenose dolphins from Sarasota in the present study needs further investigation.

4.2. *S. neurona* infections

4.2.1. Sea otters

Thomas and Cole (1996) first associated protozoa with encephalitis in sea otters and suggested a protozoa different from *T. gondii* may be involved. Rosonke et al. (1999) first reported *S. neurona* in histologic sections of brain of a captive sea otter housed in a public aquarium in Oregon. Lindsay et al. (2000, 2001a) and Miller et al. (2001a) isolated *S. neurona* in cell cultures inoculated with neural tissue of two different encephalitic free-range sea otters from California; these isolates were found to be molecularly identical with *S. neurona* isolates obtained from horses (Miller et al., 2001a; Rosenthal et al., 2001). *S. neurona* was considered the primary cause of encephalitis in both of these sea otters with proven *S. neurona* infection.

The epidemiology of *S. neurona* infections in sea otters is as intriguing as it is with *T. gondii*. Opossums (*Didelphis virginiana*) are the only known definitive host for *S. neurona* in the US (Dubey et al., 2001b). However, sarcocysts of *S. neurona* were found in a sea otter suggesting that there might be another definitive host that ingests marine mammals (Dubey et al., 2001b). Unlike *T. gondii*, opossums excrete low numbers of sporocysts/oocysts but can do it for many months whereas cats excrete large numbers of oocysts but for only 1–2 weeks. Based on limited data, *S. neurona* sporocysts are less environmentally resistant than *T. gondii* oocysts. For example, *T. gondii* oocysts have survived for 54 months at 4 °C (Dubey, 1998), whereas *S. neurona* was rendered non-infective after 18 months stored at 4 °C (JPD, unpublished).

4.2.2. Pacific harbor seals

Lapointe et al. (1998) first reported *S. neurona*-associated encephalitis in free-range Pacific harbor seals from California, and Miller et al. (2001b) isolated viable *S. neurona* from the brain and cerebrospinal fluid of an encephalitic seal in California. They found that the *S. neurona* isolated from the seal was molecularly similar to *S. neurona* from horses (Miller et al., 2001b).

4.3. *N. caninum* infections

The finding of *N. caninum* antibodies in sea otters, walruses, and dolphins in the present study is intriguing because unlike *T. gondii* and *S. neurona*, the only known definitive host (dogs) for *N. caninum* excretes relatively few oocysts (McAllister et al., 1998; Gondim et al., 2002). Furthermore, *N. caninum* oocysts have been found only in two naturally infected dogs and in both cases there were less than 100,000 oocysts present (Basso et al., 2001; Šlapeta et al., 2002).

Miller et al. (2001b) also reported a *N. caninum* titer of 1:160 in serum from an encephalitic Pacific harbor seal that had demonstrable *S. neurona* in encephalitic lesions and was also co-infected with *T. gondii*. The seal serum had a 1:160 *Neospora* IFAT titer, which

is considered to be below their cutoff value determined specific for their IFAT (Miller et al., 2001b).

For the present *N. caninum* survey, sera were tested with the *Neospora* agglutination test (NAT). Although the specificity and sensitivity of NAT has not been verified in naturally infected animals (and this may not be possible because of the difficulty of isolating *N. caninum* from naturally-infected tissues), no cross-reactivity has been found in experimentally infected animals (Romand et al., 1998). Cross-reactivity was not found between *T. gondii* and *N. caninum* in sera from walruses. Results of the present study suggest marine mammals have been exposed to *N. caninum*. The titer that should be considered specific for *N. caninum* has not been determined. Therefore, all titers are presented in Table 3. Even NAT titers of 1:25 are considered specific for *N. caninum* infection in cattle (Dubey, 2003).

4.4. *Sarcocystis canis* and other unidentified infections

S. canis is related to *S. neurona*. However, its sarcocysts, oocysts, and definitive hosts are unknown (Dubey and Speer, 1991). Congenital infections have been reported in dogs (Dubey and Speer, 1991). It can cause severe hepatitis in grizzly and black bears, chinchillas, dogs, horses, and marine mammals, and infections have been diagnosed in the US and Spain. Fatal hepatitis was diagnosed in a sea lion (Mense et al., 1992), a Hawaiian monk seal (Yantis et al., 2003), and a striped dolphin (Resendes et al., 2002a). The present sea lion case was from a different exhibit than the case reported by Mense et al. (1992). In both instances, the initial diagnosis was toxoplasmosis. The case of hepatitis in a newborn seal described by Van Pelt and Dietrich (1973) as toxoplasmosis was probably *S. canis* based on lesions and description of the parasite.

Currently there is no specific immunohistochemical test to diagnose *S. canis* because the parasite has yet to be cultivated in the laboratory. However, *S. canis* does not react with *S. neurona*, *T. gondii* and *N. caninum* antibodies. In both sea lions, protozoa were confined to the liver. Although mature schizonts of *S. canis* may be confused with *T. gondii* tissue stages, finding immature schizonts can differentiate these protozoa. *S. canis* should be considered in the diagnosis of *T. gondii*-like infections.

Acknowledgements

This live capture sea otter study was partially funded by U.S. Fish and Wildlife Service's Environmental Contaminants Division. The authors thank Sean Hahn for technical assistance, Dr. G. Bossart for the material from the Antillean manatee, and Dr. Randy Wells of Mote Marine Laboratories for the Atlantic bottlenose dolphin samples.

References

- Abbas, A.M.A., 1967. Comparative study of methods used for the isolation of *Toxoplasma gondii*. Bull. WHO 36, 344–346.
- Bandoli, J.G., de Oliveira, C.A.B., 1977. Toxoplasmose em *Sotalia guianensis* (Van Beneden, 1863) Cetacea-Delphinidae. Folha Médica 75, 459–468.

- Basso, W., Venturini, L., Venturini, M.C., Hill, D.E., Kwok, O.C.H., Shen, S.K., Dubey, J.P., 2001. First isolation of *Neospora caninum* from the feces of a naturally infected dog. *J. Parasitol.* 87, 612–618.
- Bossart, G.D., 1999. The Florida manatee on the verge of extinction. *J. Am. Vet. Med. Assoc.* 204, 1178–1183.
- Buergelt, C.D., Bonde, R.K., 1983. Toxoplasmic meningoencephalitis in a West Indian manatee. *J. Am. Vet. Med. Assoc.* 183, 1294–1296.
- Cole, R.A., Lindsay, D.S., Howe, D.K., Roderick, C.L., Dubey, J.P., Thomas, N.J., Baeten, L.A., 2000. Biological and molecular characterizations of *Toxoplasma gondii* strains obtained from southern sea otters (*Enhydra lutris nereis*). *J. Parasitol.* 86, 526–530.
- Cruickshank, J.J., Haines, D.M., Palmer, N.C., St Aubin, D.J., 1990. Cysts of a *Toxoplasma*-like organism in an Atlantic bottlenose dolphin. *Can. Vet. J.* 31, 213–215.
- De Guise, S., Lagacé, A., Béland, P., Girard, C., Higgins, R., 1995. Non-neoplastic lesions in beluga whales (*Delphinapterus leucas*) and other marine mammals from the St. Lawrence estuary. *J. Comp. Pathol.* 112, 257–271.
- Di Guardo, G., Agrimi, U., Morelli, L., Cardeti, G., Terracciano, S., Kennedy, S., 1995a. Post mortem investigations on cetaceans found stranded on the coasts of Italy between 1990 and 1993. *Vet. Rec.* 136, 439–442.
- Di Guardo, G., Corradi, A., Agrimi, U., Zizzo, N., Morelli, L., Perillo, L., Kramer, L., Cabassi, E., Kennedy, S., 1995b. Neuropathological lesions in cetaceans found stranded from 1991 to 1993 on the coasts of Italy. *Eur. J. Vet. Pathol.* 1, 47–51.
- Domingo, M., Visa, J., Pumarola, M., Marco, A.J., Ferrer, L., Rabanal, R., Kennedy, S., 1992. Pathologic and immunocytochemical studies of morbillivirus infection in striped dolphins (*Stenella coeruleoalba*). *Vet. Pathol.* 29, 1–10.
- Dubey, J.P., 1997. Validation of the specificity of the modified agglutination test for toxoplasmosis in pigs. *Vet. Parasitol.* 71, 307–310.
- Dubey, J.P., 1998. *Toxoplasma gondii* oocyst survival under defined temperatures. *J. Parasitol.* 84, 862–865.
- Dubey, J.P., 2003. Review of *Neospora caninum* and neosporosis in animals. *Korean J. Parasitol.* 41, 1–16.
- Dubey J.P., Beattie C.P., 1988. Toxoplasmosis of Animals and Man. CRC Press, Boca Raton, Florida, p. 220.
- Dubey, J.P., Desmots, G., 1987. Serological responses of equids fed *Toxoplasma gondii* oocysts. *Equine Vet. J.* 19, 337–339.
- Dubey, J.P., Hamir, A.N., 2000. Immunohistochemical confirmation of *Sarcocystis neurona* infections in raccoons, mink, cat, skunk and pony. *J. Parasitol.* 86, 1150–1152.
- Dubey, J.P., Lindsay, D.S., 1996. A review of *Neospora caninum* and neosporosis. *Vet. Parasitol.* 67, 1–59.
- Dubey, J.P., Speer, C.A., 1991. *Sarcocystis canis* n. sp. (Apicomplexa: Sarcocystidae), the etiologic agent of generalized coccidiosis in dogs. *J. Parasitol.* 77, 522–527.
- Dubey, J.P., Thulliez, P., Powell, E.C., 1995. *Toxoplasma gondii* in Iowa sows: comparison of antibody titers to isolation of *T. gondii* by bioassays in mice and cats. *J. Parasitol.* 81, 48–53.
- Dubey, J.P., Lindsay, D.S., Saville, W.J.A., Reed, S.M., Granstrom, D.E., Speer, C.A., 2001a. A review of *Sarcocystis neurona* and equine protozoal myeloencephalitis (EPM). *Vet. Parasitol.* 95, 89–131.
- Dubey, J.P., Rosypal, A.C., Rosenthal, B.M., Thomas, N.J., Lindsay, D.S., Stanek, J.F., Reed, S.M., Saville, W.J.A., 2001b. *Sarcocystis neurona* infections in sea otter (*Enhydra lutris*): evidence for natural infections with sarcocysts and transmission of infection to opossums (*Didelphis virginiana*). *J. Parasitol.* 87, 1387–1393.
- Dubey, J.P., Gamble, H.R., Hill, D., Sreekumar, C., Romand, S., Thulliez, P., 2002. High prevalence of viable *Toxoplasma gondii* infection in market weight pigs from a farm in Massachusetts. *J. Parasitol.* 88, 1234–1238.
- Dubey, J.P., Lipscomb, T.P., Mense, M., 2003. Toxoplasmosis in an elephant seal (*Mirounga angustirostris*). *J. Parasitol.* (in press).
- Gondim, L.F.P., Gao, L., McAllister, M.M., 2002. Improved production of *Neospora caninum* oocysts, cyclical oral transmission between dogs and cattle, and in vitro isolation from oocysts. *J. Parasitol.* 88, 1159–1163.
- Gulland, F.M., Lowenstine, L.J., Lapointe, J.M., Spraker, T., King, D.P., 1997. Herpesvirus infection in stranded Pacific Harbor seals of coastal California. *J. Wildl. Dis.* 33, 450–458.
- Holshuh, H.J., Sherrod, A.E., Taylor, C.R., Andrews, B.F., Howard, E.B., 1985. Toxoplasmosis in a feral northern fur seal. *J. Am. Vet. Med. Assoc.* 187, 1229–1230.
- Inskeep, W., Gardiner, C.H., Harris, R.K., Dubey, J.P., Goldston, R.T., 1990. Toxoplasmosis in Atlantic bottle-nosed dolphins (*Tursiops truncatus*). *J. Wildl. Dis.* 26, 377–382.
- Jardine, J.E., Dubey, J.P., 2002. Congenital toxoplasmosis in an Indo-Pacific bottlenose dolphin (*Tursiops aduncus*). *J. Parasitol.* 88, 197–199.

- Lambourn, D.M., Jeffries, S.J., Dubey, J.P., 2001. Seroprevalence of *Toxoplasma gondii* in harbor seals (*Phoca vitulina*) in southern Puget Sound Washington. *J. Parasitol.* 87, 1196–1197.
- Lapointe, J.M., Duignan, P.J., Barr, B.C., Petrich, A.K., MacPherson, D.W., Gulland, F.M., Dubey, J.P., 2003. Meningoencephalitis associated with an unidentified apicomplexan protozoan in a Pacific harbor seal, *J. Parasitol.* 89, 859–862.
- Lapointe, J.M., Duignan, P.J., Marsh, A.E., Gulland, F.M., Barr, B.C., Naydan, D.K., King, D.P., Farman, C.A., Burek-Huntingdon, K.A., Lowenstine, L.J., 1998. Meningoencephalitis due to a *Sarcocystis neurona*-like protozoan in Pacific harbor seals (*Phoca vitulina richardsi*). *J. Parasitol.* 84, 1184–1189.
- Lindsay, D.S., Dubey, J.P., 1989. Immunohistochemical diagnosis of *Neospora caninum* in tissue sections. *Am. J. Vet. Res.* 50, 1981–1983.
- Lindsay, D.S., Thomas, N.J., Dubey, J.P., 2000. Biological characterization of *Sarcocystis neurona* from a Southern sea otter (*Enhydra lutris nereis*). *Int. J. Parasitol.* 30, 617–624.
- Lindsay, D.S., Thomas, N.J., Rosypal, A.C., Dubey, J.P., 2001a. Dual *Sarcocystis neurona* and *Toxoplasma gondii* infection in a Northern sea otter from Washington state, USA. *Vet. Parasitol.* 97, 319–327.
- Lindsay, D.S., Phelps, K.K., Smith, S.A., Flick, G., Sumner, S.S., Dubey, J.P., 2001b. Removal of *Toxoplasma gondii* oocyst from seawater by eastern oysters (*Crassostrea virginica*). *J. Eukaryot. Microbiol.* 2001, 197S–198S.
- McAllister, M.M., Dubey, J.P., Lindsay, D.S., Jolley, W.R., Wills, R.A., McGuire, A.M., 1998. Dogs are definitive hosts of *Neospora caninum*. *Int. J. Parasitol.* 28, 1473–1478.
- Mense, M.G., Dubey, J.P., Homer, B.L., 1992. Acute hepatic necrosis associated with a *Sarcocystis*-like protozoa in a sea lion (*Zalophus californianus*). *J. Vet. Deign. Invest.* 4, 486–490.
- Migaki, G., Allen, J.F., Casey, H.W., 1977. Toxoplasmosis in a California sea lion (*Zalophus californianus*). *Am. J. Vet. Res.* 38, 135–136.
- Mikaelian, I., Boisclair, J., Dubey, J.P., Kennedy, S., Martineau, D., 2000. Toxoplasmosis in beluga whales (*Delphinapterus leucas*) from the St. Lawrence estuary: two case reports and a serologic survey. *J. Comp. Pathol.* 122, 73–76.
- Miller, M.A., Crosbie, P.R., Sverlow, K., Hanni, K., Barr, B.C., Kock, N., Murray, M.J., Lowenstine, L.J., Conrad, P.A., 2001a. Isolation and characterization of *Sarcocystis* from brain tissue of a free-living southern sea otter (*Enhydra lutris nereis*) with fatal meningoencephalitis. *Parasitol. Res.* 87, 252–257.
- Miller, M.A., Sverlow, K., Crosbie, P.R., Barr, B.C., Lowenstine, L.J., Gulland, F.M., Packham, A., Conrad, P.A., 2001b. Isolation and characterization of two parasitic protozoa from a Pacific harbor seal (*Phoca vitulina richardsi*) with meningoencephalomyelitis. *J. Parasitol.* 87, 816–822.
- Miller, M.A., Gardner, I.A., Kreuder, C., Paradies, D.M., Worcester, K.R., Jessup, D.A., Dodd, E., Harris, M.D., Ames, J.A., Packham, A.E., Conrad, P.A., 2002a. Coastal freshwater runoff is a risk factor for *Toxoplasma gondii* infection of southern sea otters (*Enhydra lutris nereis*). *Int. J. Parasitol.* 32, 997–1006.
- Miller, M.A., Gardner, I.A., Packham, A., Mazet, J.K., Hanni, K.D., Jessup, D., Estes, J., Jameson, R., Dodd, E., Barr, B.C., Lowenstine, L.J., Gulland, F.M., Conrad, P.A., 2002b. Evaluation of an indirect fluorescent antibody test (IFAT) for demonstration of antibodies to *Toxoplasma gondii* in the sea otter (*Enhydra lutris*). *J. Parasitol.* 88, 594–599.
- Ratcliffe, H.L., Worth, C.B., 1951. Toxoplasmosis of captive wild birds and mammals. *Am. J. Pathol.* 27, 655–667.
- Reidarson, T.H., McBain, J., House, C., King, D.P., Scott, J.L., Krafft, A., Taubenberger, J.K., Heyning, J., Lipscomb, T.P., 1998. Morbillivirus infection in stranded common dolphins from the Pacific Ocean. *J. Wildl. Dis.* 34, 771–776.
- Resendes, A.R., Juan-Sallés, C., Almería, S., Majó, N., Domingo, M., Dubey, J.P., 2002a. Hepatic sarcocystosis in a striped dolphin (*Stenella coeruleoalba*) from the Spanish Mediterranean coast. *J. Parasitol.* 88, 206–209.
- Resendes, A.R., Almería, S., Dubey, J.P., Obón, E., Juan-Sallés, C., Degollada, E., Alegre, F., Cabezón, O., Pont, S., Domingo, M., 2002b. Disseminated toxoplasmosis in a Mediterranean pregnant Risso's dolphin (*Grampus griseus*) with transplacental fetal infection. *J. Parasitol.* 88, 1029–1032.
- Riemann, H.P., Behymer, D.E., Fowler, M.E., Schulz, T., Lock, A., Orthofer, J.G., Silverman, S., Franti, C.E., 1974. Prevalence of antibodies to *Toxoplasma gondii* in captive exotic mammals. *J. Am. Vet. Med. Assoc.* 165, 798–800.
- Rosenthal, B.M., Lindsay, D.S., Dubey, J.P., 2001. Relationships among *Sarcocystis* species transmitted by New World opossums (*Didelphis* spp.). *Vet. Parasitol.* 95, 133–142.

- Romand, S., Thulliez, P., Dubey, J.P., 1998. Direct agglutination test for serologic diagnosis of *Neospora caninum* infection. *Parasitol. Res.* 84, 50–53.
- Rosonke, B.J., Brown, S.R., Tornquist, S.J., Snyder, S.P., Garner, M.M., Blythe, L.L., 1999. Encephalomyelitis associated with a *Sarcocystis neurona*-like organism in a sea otter. *J. Am. Vet. Med. Assoc.* 215, 1839–1842.
- Schulman, F.Y., Lipscomb, T.P., Moffett, D., Krafft, A.E., Lichy, J.H., Tsai, M.M., Taubenberger, J.K., Kennedy, S., 1997. Histologic, immunohistological, and polymerase chain reaction studies of bottlenose dolphins from the 1987–1988 United States Atlantic coast epizootic. *Vet. Pathol.* 34, 288–295.
- Šlapeta, J.R., Modry, D., Kyselova, I., Horejs, R., Lukes, J., Koudela, B., 2002. Dog shedding oocysts of *Neospora caninum*: PCR diagnosis and molecular phylogenetic approach. *Vet. Parasitol.* 109, 157–167.
- Thomas, N.J., Cole, R.A., 1996. The risk of disease and threats to the wild population. *Endangered species update. Conserv. Manage. Southern Sea Otter* 13, 23–27 (Special Issue).
- Thulliez, P., Remington, J.S., Santoro, F., Ovlaque, G., Sharma, S.D., Desmots, G., 1986. Une nouvelle reaction d'agglutination pour le diagnostic du stade evolutif de la Toxoplasmose acquise. *Pathol. Biol.* 34, 173–177.
- Van Pelt, R.W., Dietrich, R.A., 1973. Staphylococcal infection and toxoplasmosis in a young harbor seal. *J. Wildl. Dis.* 9, 258–261.
- Yantis, D., Moeller, R., Braun, R., Gardiner, C.H., Aguirre, A., Dubey, J.P. 2003. Hepatitis associated with a *Sarcocystis canis*-like protozoan in a Hawaiian monk seal (*Monachus schauinslandi*). *J. Parasitol.* (in press).