Review Article

Current Concepts

Acute Human Immunodeficiency Virus Type 1 Infection

James O. Kahn, M.D., and Bruce D. Walker, M.D.

ACUTE human immunodeficiency virus type 1 (HIV-1) infection is a transient symptomatic illness associated with high-titer HIV-1 replication and a robust and expansive immunologic response to the invading pathogen. From 40 to 90 percent of new HIV-1 infections are associated with symptomatic illness. This syndrome is often undiagnosed or misdiagnosed, since HIV-1 antibodies are usually not detected during the early phase of infection. The diagnosis of acute HIV-1 infection requires a high index of clinical suspicion and correct use of specific diagnostic laboratory tests. Accurate early diagnosis is now particularly important because of the potential clinical benefit of early antiretroviral therapy.

More than 30 million persons are estimated to be infected with HIV-1 worldwide.[1] In the United States, more than 44,000 new cases of infection will occur in 1998, and globally, there are an estimated 16,000 new cases daily.[1,2] The annual risk of HIV-1 infection in particular groups, such as young men who have sex with men, injection-drug users, and users of "crack" cocaine, may be as high as 4 to 5 percent per year.[3,4] Recent increases in the rates of gonorrhea and other sexually transmitted diseases suggest that the rates of HIV-1 infection will also increase.[5] Identifying persons in the initial stage of HIV-1 infection is essential for initiating early antiretroviral therapy and for preventing the spread of infection. Here we review the pathogenesis, clinical manifestations, diagnosis, and treatment of acute HIV-1 infection.

From the AIDS Program, San Francisco General Hospital and the University of California, San Francisco (J.O.K.), and Partners AIDS Research Center, Massachusetts General Hospital and Harvard Medical School, Boston (B.D.W.). Address reprint requests to Dr. Walker at the Partners AIDS Research Center, Massachusetts General Hospital, 149 13th St., Charlestown, MA 02129.

©1998, Massachusetts Medical Society.

PATHOGENESIS

The most common mode of HIV-1 infection is sexual transmission at the genital mucosa.[6] Recent studies in rhesus monkeys with acute intravaginal simian immunodeficiency virus infection provide important insights into the sequence of cellular events occurring in the earliest stages of infection.[7] In this model, the first cellular targets of the virus are Langerhans' cells, tissue dendritic cells found in the lamina propria subjacent to the cervicovaginal epithelium (Fig. 1). These cells then fuse with CD4+ lymphocytes and spread to the deeper tissues. Within two days after infection, virus can be detected in the draining internal iliac lymph nodes. Shortly thereafter, systemic dissemination occurs, and HIV-1 can be cultured from plasma five days after infection.[7] In humans, there appears to be some variation in the time from mucosal infection to initial viremia, with estimates ranging from 4 to 11 days.[9] Breaks in the mucosal barrier and increased inflammation due to the presence of genital ulcer disease, urethritis, or cervicitis increase the risk of acquiring HIV-1 infection.[10] Although infection is transmitted most frequently across the genital mucosa, numerous reports demonstrate that infection can also be transmitted across the oral mucosa as a result of genital–oral sex.[11-15] Nasopharyngeal tonsil and adenoid tissues are rich in cells of dendritic origin, which are probably the initial target cells, facilitating the transmission of the virus to CD4+ cells.[16]

Studies of persons with acute HIV-1 infection demonstrate selective infection by certain populations of HIV-1 variants. Transmitted viruses are typically macrophage-tropic (not T-cell–tropic) and lack the ability to induce multinucleated syncytia in tissue culture.[17,18] Glycoprotein 120, the viral-envelope protein, binds to the CD4 molecule on susceptible cells, but cell entry requires the presence of a coreceptor.[19] The coreceptor for macrophage-tropic strains is CCR5, a surface chemokine receptor.[20,21] Such viruses have recently been renamed R5 viruses to reflect their coreceptor requirement, whereas T-cell–tropic viruses, which require CXCR4 for entry, are termed X4 viruses.[8] Langerhans' cells, the earliest target of the virus, express CCR5 but may not express CXCR4, the coreceptor required for the entry of X4 viral isolates.[22] This may explain why R5 viruses are the predominant strains transmitted during acute HIV-1 infection. This receptor pattern also explains why persons who are homozygous for a 32-bp deletion in CCR5 (CCR5Δ32) are relatively resistant to infection with the usual R5 strains,[23,24]

Downloaded from www.nejm.org at VA LIBRARY NETWORK on August 16, 2004.
Copyright © 1998 Massachusetts Medical Society. All rights reserved.

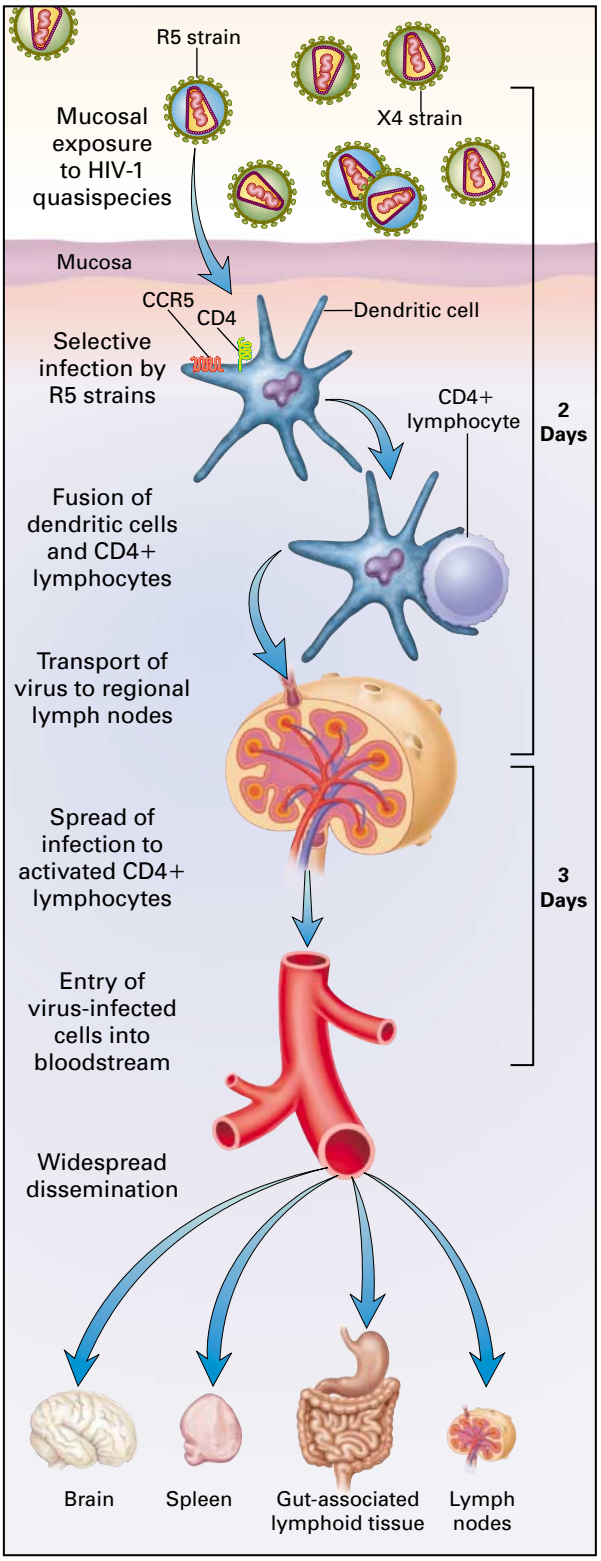

Figure 1. Early Events in Transmucosal HIV-1 Infection.

The arrows indicate the path of the virus. The viral-envelope protein binds to the CD4 molecule on dendritic cells. Entry into the cells requires the presence of CCR5, a surface chemokine receptor. Dendritic cells, which express the viral coreceptors CD4 and CCR5, are selectively infected by R5 (macrophage-tropic) strains.[8] Within two days after mucosal exposure, virus can be detected in lymph nodes. Within another three days, it can be cultured from plasma.

although rare cases of transmission of X4 viruses have recently been reported in such persons.[25,26]

After infection, there is a rapid rise in plasma viremia, with widespread dissemination of the virus associated with seeding of lymphoid organs[27-29] and trapping of virus by follicular dendritic cells.[30] High titers of virus are likely to be present in the genital tract during primary infection. This stage, characterized by high levels of replicating virus and infectivity, has important public health implications, since routine tests for HIV-1 antibody fail to detect the new infection.

After the initial rise in plasma viremia, often to levels in excess of 1 million RNA molecules per milliliter,[31,32] there is a marked reduction from the peak viremia to a steady-state level of viral replication.[33-36] The decrease in the viral load during acute HIV-1 infection is probably due to virus-specific immune responses that limit viral replication. There is a temporal relation between the appearance of HIV-1–specific cytotoxic T lymphocytes and declining viral titers in humans[36,37] and in animals.[38] During acute infection, 1 in 17 CD8+ T cells in the peripheral blood may be a cytotoxic T lymphocyte specifically targeted against the virus.[39,40] This high proportion reflects a vigorous attempt by host cellular immune defenses to contain the massive viral replication. These observations, coupled with in vitro evidence of a potent antiviral effect of cytotoxic T lymphocytes,[41] suggest that these cells are at least partly responsible for the reduction in HIV-1 viremia. There is also a correlation between cytotoxic-T-lymphocyte responses to the envelope protein and the reduction in plasma viral RNA.[42] In addition, soluble factors produced by CD8+ cells inhibit HIV-1 replication in the early stages of acute infection[43] and may thus contribute to the reduction of the viral load. In contrast, neutralizing antibodies are not usually detectable until weeks to months after the reduction in replicating virus.[36] Many of the symptoms of acute HIV-1 infection may reflect the immune response to the virus,[44] and the symptoms usually resolve as the viral load in the plasma decreases.

After the initial drop in viremia, a viral set-point is established. Persons with the highest viral loads have the most rapid rates of progression to the acquired immunodeficiency syndrome and death.[45]

Downloaded from www.nejm.org at VA LIBRARY NETWORK on August 16, 2004.
Copyright © 1998 Massachusetts Medical Society. All rights reserved.

Studies in animals suggest that lowering the viral load during primary infection results in a lower set-point.[46] The factors determining this set-point may be related to genetic differences in coreceptors[47,48] or qualitative differences in the immune response.[49-52] A more broadly directed cytotoxic-T-lymphocyte response in the early stages of HIV-1 infection is associated with a subsequently lower viral load and slower progression of disease,[53] suggesting that containment of viremia by this immune response in the early stages of infection may have a clinical benefit. Differences in the virulence of viral strains may also modulate the set-point. Less virulent strains have attenuated replication, which is associated with lower levels of viremia and slower disease progression.[54,55]

SIGNS AND SYMPTOMS

The signs and symptoms of acute HIV-1 infection usually present within days to weeks after initial exposure. The most common signs and symptoms (Table 1) include fever (median maximal temperature, 38.9°C),[11] fatigue, rash that is usually maculopapular but may have protean presentations, headache, lymphadenopathy, pharyngitis, myalgia, arthralgia, aseptic meningitis, retro-orbital pain, weight loss, depression, gastrointestinal distress, night sweats, and oral or genital ulcers. The acute illness may last from a few days to more than 10 weeks, but the duration is usually less than 14 days.[11] The severity and the duration of the illness may have prognostic implications; severe and prolonged symptoms are correlated with rapid disease progression.[56,57] The nonspecific nature of these symptoms presents a major challenge to health care providers and underscores the need to obtain an accurate history of exposure. An evaluation for acute HIV-1 infection should be performed if a patient has signs and symptoms that are consistent with the diagnosis and a history of exposure to a person with known or possible HIV-1 infection. Acute infection should also be considered in persons presenting with a sexually transmitted disease.

Some symptoms are particularly suggestive of acute HIV-1 infection in a person with a compatible history of exposure. A morbilliform rash (also described as maculopapular), usually involving the trunk, occurs in 40 to 80 percent of persons with symptomatic acute HIV-1 infection. Rash may be difficult to detect in darkly pigmented people. Histopathological evaluation of the involved skin shows a mononuclear-cell infiltrate of the superficial dermal vessels, consisting mainly of CD4+ cells, and focal lymphocytic vasculitis.[58] Panels A and B in Figure 2 show cutaneous manifestations of acute HIV-1 infection. An acute meningoencephalitis syndrome has been reported as another presentation of acute HIV-1 infection, and this syndrome should be considered in the differential diagnosis of aseptic meningitis.[11,59] Mucocutaneous ulceration, which can involve the buccal mucosa, gingiva, palate, esophagus, anus, or penis, is also highly suggestive of acute infection in a person at risk.[11,60-62] An oral ulcer with mucocutaneous candidiasis in a patient with acute HIV-1 infection is shown in Figure 2C.

TABLE 1. FREQUENCY OF SYMPTOMS AND FINDINGS ASSOCIATED WITH ACUTE HIV-1 INFECTION.

SYMPTOM OR FINDING	PERCENTAGE OF PATIENTS
Fever	>80–90
Fatigue	>70–90
Rash	>40–80
Headache	32–70
Lymphadenopathy	40–70
Pharyngitis	50–70
Myalgia or arthralgia	50–70
Nausea, vomiting, or diarrhea	30–60
Night sweats	50
Aseptic meningitis	24
Oral ulcers	10–20
Genital ulcers	5–15
Thrombocytopenia	45
Leukopenia	40
Elevated hepatic-enzyme levels	21

In a group of 23 persons at risk of HIV infection who were followed every six months and who became infected, 87 percent had symptomatic acute infection, and 95 percent of these patients sought medical evaluation.[11] But only one in four persons in the study received the appropriate diagnosis of acute HIV-1 infection at the first clinic visit, even though there should have been a high index of suspicion. Because the signs and symptoms are nonspecific, acute HIV-1 infection is frequently confused with a variety of other illnesses, including infectious mononucleosis, secondary syphilis, acute infection with hepatitis A or B, roseola or other viral infections, and toxoplasmosis. Acute HIV-1 infection should therefore be included in the differential diagnosis of any unexplained severe febrile illness. The nonspecific symptoms of acute HIV-1 infection make it difficult to determine the true frequency of symptomatic illness in newly infected persons. Estimates of the frequency range from 40 to 90 percent, but these studies have not included control groups. In a recent study in India, 81 percent of persons with acute HIV-1 infection seen at a clinic for sexually transmitted diseases had at least one of the following eight signs or symptoms: fever, adenopathy, joint pain, thrush, pharyngitis, rash, diarrhea, and paresthesia.[31]

Laboratory studies performed during the initial infection may show lymphopenia and thrombocytopenia, but atypical lymphocytes are infrequent. The

Downloaded from www.nejm.org at VA LIBRARY NETWORK on August 16, 2004.
Copyright © 1998 Massachusetts Medical Society. All rights reserved.

A

B

C

Figure 2. Cutaneous Manifestations of Acute HIV-1 Infection.

Panels A and B show the rash associated with acute infection, which is more prominent centrally than peripherally and may involve the face. The lesions are 5 to 10 mm in diameter and are erythematous, nonpruritic, and painless. Panel C shows an oral ulceration in a person with acute HIV-1 infection who also presented with thrush. The photographs were kindly provided by Charles Farthing (Panel A), Donald Abrams (Panel B), and Ginat W. Mirowski (Panel C).

Downloaded from www.nejm.org at VA LIBRARY NETWORK on August 16, 2004.
Copyright © 1998 Massachusetts Medical Society. All rights reserved.

characteristic laboratory findings are not unique to HIV-1 infection but are also observed in other acute viral illnesses. The CD4+ cell count usually decreases during acute HIV-1 infection but may remain in the normal range; typically, over the ensuing weeks, the CD4+ cell count decreases, the CD8+ cell count increases, and the ratio of CD4+ cells to CD8+ cells is inverted.[11,60-64]

Most persons with acute HIV-1 infection do not expect to receive this diagnosis even if they have had recent risky exposures. Clinicians should take a careful history for HIV-1 exposure and should anticipate that their patients will be anxious and fearful when the diagnosis is entertained. It is essential at this stage to address the patients' concerns, explain the planned evaluation, and describe possible treatment options.

DIAGNOSIS

The diagnosis of acute HIV-1 infection cannot be made with standard serologic tests. The recombinant enzyme-linked immunosorbent assays (ELISAs) commonly used to diagnose established HIV-1 infection are usually negative in persons who present with acute infection. Serologic tests first become positive approximately 22 to 27 days after acute infection.[65] Tests for use at home also rely on antibody production and will not detect acute HIV-1 infection.

The only test licensed for earlier detection of HIV-1 infection is the serum or plasma p24 antigen test, which is used routinely in blood donors to detect viral infection before the development of HIV-1 antibodies. Cases of acute HIV-1 infection have also been accurately diagnosed on the basis of high plasma viral RNA levels.[31,32] The detection of high-titer viral RNA or viral p24 antigen in a patient with a negative test for HIV-1 antibodies establishes the diagnosis of acute HIV-1 infection.[32,66] The viral-RNA assay appears to be the more sensitive of the two tests, and it has been estimated to detect HIV-1 infection three to five days earlier than the p24 antigen test[65,67] and one to three weeks earlier than standard serologic tests.[68] In our experience, the levels of viral RNA are always higher than 50,000 molecules per milliliter in patients with symptomatic acute HIV-1 infection. In a recent study of nine persons with acute HIV-1 infection, all nine had viral levels in excess of 300,000 molecules per milliliter, and seven of the nine had levels in excess of 1 million molecules per milliliter (unpublished data). Lower levels of HIV-1 RNA might be expected with longer intervals after the onset of symptoms, since the immune system exerts control over the ongoing viral replication. It is important to be aware that in rare cases, very low levels of HIV-1 RNA in plasma (<3000 RNA molecules per milliliter) may represent false positive results (unpublished data). Such low values, which need to be confirmed, are unlikely to represent acute infection. Subsequent documentation of seroconversion is essential to confirm the diagnosis of HIV-1 infection. Although infection without eventual seroconversion has been reported, it is rare.[69]

A blood sample should be obtained for both HIV-1 RNA testing (or p24 antigen testing, if HIV-1 RNA testing is not available) and HIV ELISA when a patient at risk presents with the signs and symptoms of the syndrome along with a compatible history of exposure. If these laboratory studies fail to detect HIV-1 infection, then other pathogens should be considered in the differential diagnosis. HIV ELISA and HIV-1 RNA tests should be repeated two to four weeks after the resolution of symptoms in high-risk persons. In addition, counseling about the avoidance of high-risk behavior should be initiated.

TREATMENT

Evidence of the benefit of treatment during acute HIV-1 infection stems in part from the observation that the initial viral isolates represent a relatively homogeneous swarm of viruses[17,18] and may therefore be susceptible to effective combination therapy. In addition, early intervention has been shown to restore important virus-specific cellular immune responses that appear to be involved in host responses that control viremia.[32] Early treatment may also limit the extent of viral dissemination, restrict damage to the immune system, protect antigen-presenting cells, and reduce the chance of disease progression. A panel of experts recently recommended that immediate therapy be considered for persons with acute HIV-1 infection.[70]

Data in support of early therapy are limited. The only randomized, placebo-controlled study of antiretroviral therapy initiated during primary HIV-1 infection involved patients with a history consistent with acute HIV-1 infection or known recent exposure to HIV-1 and laboratory evidence of recent infection.[71] The patients were randomly assigned to receive either zidovudine (250 mg twice a day, a regimen considered inadequate according to current standards) or placebo for six months. After six months of treatment, the patients randomly assigned to receive zidovudine had a mean increase of 173 CD4+ lymphocytes per cubic millimeter, as compared with an increase of 6 CD4+ lymphocytes per cubic millimeter in the placebo group.

Early therapy consisting of two nucleoside reverse-transcriptase inhibitors plus an HIV-1–protease inhibitor or three agents targeted to reverse transcriptase has also been investigated in several studies. Treatment with two nucleoside reverse-transcriptase inhibitors and a protease inhibitor reduced HIV-1 RNA to undetectable levels with corresponding increases in CD4+ cells, increases in the CD4+:CD8+ ratio, and reductions in proviral DNA levels and antibody.[72-74] Although virus persisted in resting CD4+ cells,[75] these studies indicate that complete or nearly

Downloaded from www.nejm.org at VA LIBRARY NETWORK on August 16, 2004.
Copyright © 1998 Massachusetts Medical Society. All rights reserved.

complete suppression of viral replication can be achieved as long as therapy is maintained.[75,76]

Perhaps the most compelling data in support of early therapy come from studies of persons treated with potent triple-drug combination therapy during acute HIV-1 infection. In each of six persons who received this therapy, HIV-1 RNA levels rapidly decreased to values below the limits of quantitation, and the reduction in the viral load was associated with vigorous HIV-1–specific responses of CD4+ T helper cells to the p24 protein, like the responses seen in nonprogressive infection[32] (and unpublished data). These data suggest that there is an early opportunity to restore certain immune responses that may be associated with slower disease progression and that this opportunity may be lost if therapy is delayed. Clinical trials with extended follow-up will be required to determine whether such early therapy confers a long-term benefit.

The final decision to start antiviral therapy in persons presenting with acute HIV-1 infection should include a plan to ensure adherence to the complicated treatment regimens and acknowledgment that the long-term clinical benefits of early treatment are unknown. In the face of a diagnosis of HIV-1 infection, patients need support, information, and guidance. If a patient opts to start therapy, as we recommend for all our patients with acute HIV-1 infection, then sustained adherence to the medication regimen must be emphasized. Inconsistent adherence leads to viral resistance and severely limits future treatment options.[70] In some patients with chronic HIV-1 infection, viral suppression has been maintained during more than two years of continuous therapy,[75,76] and treatment initiated during acute HIV-1 infection is likely to be at least as successful.

CONCLUSIONS

Acute HIV-1 infection, which often presents as an acute febrile illness that is undiagnosed or misdiagnosed, should be considered in the differential diagnosis in any sexually active or otherwise at-risk person presenting with an acute febrile illness. If acute HIV-1 infection is suspected, HIV-1 RNA and HIV-1 ELISA testing should be performed. The use of quantitative HIV-1 RNA testing (or, if unavailable, p24 antigen testing) allows for the diagnosis of acute HIV-1 infection before standard ELISAs detect HIV-1 antibodies. Once the diagnosis has been established, early treatment with maximally suppressive combination agents should be considered. Adherence to the complicated regimens is essential if early therapy is initiated. Identification of the source of exposure in persons with primary HIV-1 infection may reveal networks of newly infected or highly infectious persons for whom referral and treatment may be beneficial, which in turn may reduce the chance of spread to others.

Supported by grants from the Center for AIDS Research (P30 AI 27763), the AIDS Clinical Research Center, San Francisco (CC96-SF-176), and the National Institutes of Health (R37 AI28568 and UO1 41531).

We are indebted to Martin S. Hirsch, Thomas Quinn, Barney Graham, and Frederick Hecht for their critical review of the manuscript.

REFERENCES

1. Report on the global HIV/AIDS epidemic. Geneva: UNAIDS, 1998.
2. Update: trends in AIDS incidence — United States, 1996. MMWR Morb Mortal Wkly Rep 1997;46:861-7.
3. Osmond DH, Page K, Wiley J, et al. HIV infection in homosexual and bisexual men 18 to 29 years of age: the San Francisco Young Men's Health Study. Am J Public Health 1994;84:1933-7.
4. Nelson KE, Vlahov D, Galai N, Astemborski J, Solomon L. Preparations for AIDS vaccine trials: incident human immunodeficiency virus (HIV) infections in a cohort of injection drug users in Baltimore, Maryland. AIDS Res Hum Retroviruses 1994;10:Suppl 2:S201-S205.
5. Gonorrhea among men who have sex with men — selected sexually transmitted diseases clinics, 1993–1996. MMWR Morb Mortal Wkly Rep 1997;46:889-92.
6. Royce RA, Seña A, Cates W Jr, Cohen MS. Sexual transmission of HIV. N Engl J Med 1997;336:1072-8.
7. Spira AI, Marx PA, Patterson BK, et al. Cellular targets of infection and route of viral dissemination after an intravaginal inoculation of simian immunodeficiency virus into rhesus macaques. J Exp Med 1996;183:215-25.
8. Berger EA, Doms RW, Fenyö E-M, et al. A new classification for HIV-1. Nature 1998;391:240.
9. Niu MT, Jermano JA, Reichelderfer P, Schnittman SM. Summary of the National Institutes of Health workshop on primary human immunodeficiency virus type 1 infection. AIDS Res Hum Retroviruses 1993;9:913-24.
10. Mehendale SM, Rodrigues JJ, Brookmeyer RS, et al. Incidence and predictors of human immunodeficiency virus type 1 seroconversion in patients attending sexually transmitted disease clinics in India. J Infect Dis 1995;172:1486-91.
11. Schacker T, Collier AC, Hughes J, Shea T, Corey L. Clinical and epidemiologic features of primary HIV infection. Ann Intern Med 1996;125:257-64. [Erratum, Ann Intern Med 1997;126:174.]
12. Berrey MM, Shea T. Oral sex and HIV transmission. J Acquir Immune Defic Syndr Hum Retrovirol 1997;14:475.
13. Lifson AR, O'Malley PM, Hessol NA, Buchbinder SP, Cannon L, Rutherford GW. HIV seroconversion in two homosexual men after receptive oral intercourse with ejaculation: implications for counseling concerning safe sexual practices. Am J Public Health 1990;80:1509-11.
14. Lane HC, Holmberg SD, Jaffe HW. HIV seroconversion and oral intercourse. Am J Public Health 1991;81:658.
15. Goldberg DJ, Green ST, Kennedy DH, Emslie JA, Black JD. HIV and orogenital transmission. Lancet 1988;2:1363.
16. Frankel SS, Wenig BM, Burke AP, et al. Replication of HIV-1 in dendritic cell-derived syncytia at the mucosal surface of the adenoid. Science 1996;272:115-7.
17. Zhu T, Mo H, Wang N, et al. Genotypic and phenotypic characterization of HIV-1 patients with primary infection. Science 1993;261:1179-81.
18. Zhu T, Wang N, Carr A, et al. Genetic characterization of human immunodeficiency virus type 1 in blood and genital secretions: evidence for viral compartmentalization and selection during sexual transmission. J Virol 1996;70:3098-107.
19. Feng Y, Broder CC, Kennedy PE, Berger EA. HIV-1 entry cofactor: functional cDNA cloning of a seven-transmembrane, G protein-coupled receptor. Science 1996;272:872-7.
20. Alkhatib G, Combadiere C, Broder CC, et al. CC CKR5: a RANTES, MIP-1α, MIP-1β receptor as a fusion cofactor for macrophage-tropic HIV-1. Science 1996;272:1955-8.
21. Dragic T, Litwin V, Allaway GP, et al. HIV-1 entry into CD4+ cells is mediated by the chemokine receptor CC-CKR-5. Nature 1996;381:667-73.
22. Zaitseva M, Blauvelt A, Lee S, et al. Expression and function of CCR5 and CXCR4 on human Langerhans cells and macrophages: implications for HIV primary infection. Nat Med 1997;3:1369-75.
23. Paxton WA, Martin SR, Tse D, et al. Relative resistance to HIV-1 infection of CD4 lymphocytes from persons who remain uninfected despite multiple high-risk sexual exposure. Nat Med 1996;2:412-7.
24. Liu R, Paxton WA, Choe S, et al. Homozygous defect in HIV-1 coreceptor accounts for resistance in some multiply-exposed individuals to HIV-1 infection. Cell 1996;86:367-77.
25. Biti R, Ffrench R, Young J, Bennetts B, Stewart G, Liang T. HIV-1 infection in an individual homozygous for the CCR5 deletion allele. Nat Med 1997;3:252-3.

Downloaded from www.nejm.org at VA LIBRARY NETWORK on August 16, 2004.
Copyright © 1998 Massachusetts Medical Society. All rights reserved.

26. O'Brien TR, Winkler C, Dean M, et al. HIV-1 infection in a man homozygous for CCR5 delta 32. Lancet 1997;349:1219.
27. Cavert W, Notermans DW, Staskus K, et al. Kinetics of response in lymphoid tissues to antiretroviral therapy of HIV-1 infection. Science 1997;276:960-4. [Erratum, Science 1997;276:1321.]
28. Embretson J, Zupancic M, Ribas JL, et al. Massive covert infection of helper T lymphocytes and macrophages by HIV during the incubation period of AIDS. Nature 1993;362:359-62.
29. Pantaleo G, Graziosi C, Demarest JF, et al. HIV infection is active and progressive in lymphoid tissue during the clinically latent stage of disease. Nature 1993;362:355-8.
30. Heath SL, Tew JG, Tew JG, Szakal AK, Burton GF. Follicular dendritic cells and human immunodeficiency virus infectivity. Nature 1995;377:740-4.
31. Bollinger RC, Brookmeyer RS, Mehendale SM, et al. Risk factors and clinical presentation of acute primary HIV infection in India. JAMA 1997; 278:2085-9.
32. Rosenberg ES, Billingsley JM, Caliendo AM, et al. Vigorous HIV-1-specific CD4+ T cell responses associated with control of viremia. Science 1997;278:1447-50.
33. Clark SJ, Saag MS, Decker WD, et al. High titers of cytopathic virus in plasma of patients with symptomatic primary HIV-1 infection. N Engl J Med 1991;324:954-60.
34. Daar ES, Moudgil T, Meyer RD, Ho DD. Transient high levels of viremia in patients with primary human immunodeficiency virus type 1 infection. N Engl J Med 1991;324:961-4.
35. Piatak M Jr, Saag MS, Yang LC, et al. High levels of HIV-1 in plasma during all stages of infection determined by competitive PCR. Science 1993;259:1749-54.
36. Koup RA, Safrit JT, Cao Y, et al. Temporal association of cellular immune responses with the initial control of viremia in primary human immunodeficiency virus type 1 syndrome. J Virol 1994;68:4650-5.
37. Borrow P, Lewicki H, Hahn BH, Shaw GM, Oldstone MBA. Virus-specific CD8+ cytotoxic T-lymphocyte activity associated with control of viremia in primary human immunodeficiency virus type 1 infection. J Virol 1994;68:6103-10.
38. Yasutomi Y, Reimann KA, Lord CI, Miller MD, Letvin NL. Simian immunodeficiency virus-specific CD8+ lymphocyte response in acutely infected rhesus monkeys. J Virol 1993;67:1707-11.
39. Borrow P, Lewicki H, Wei X, et al. Antiviral pressure exerted by HIV-1-specific cytotoxic T lymphocytes (CTLs) during primary infection demonstrated by rapid selection of CTL escape virus. Nat Med 1997;3:205-11.
40. Yang OO, Kalams SA, Rosenzweig M, et al. Efficient lysis of human immunodeficiency virus type 1-infected cells by cytotoxic T lymphocytes. J Virol 1996;70:5799-806.
41. Yang OO, Kalams SA, Trocha A, et al. Suppression of human immunodeficiency virus type 1 replication by CD8+ cells: evidence for HLA class I-restricted triggering of cytolytic and noncytolytic mechanisms. J Virol 1997;71:3120-8.
42. Musey L, Hughes J, Schacker T, Shea T, Corey L, McElrath MJ. Cytotoxic-T-cell responses, viral load, and disease progression in early human immunodeficiency virus type 1 infection. N Engl J Med 1997;337:1267-74.
43. Mackewicz CE, Yang LC, Lifson JD, Levy JA. Non-cytolytic CD8 T-cell anti-HIV responses in primary HIV-1 infection. Lancet 1994;344:1671-3.
44. Cossarizza A. T-cell repertoire and HIV infection: facts and perspectives. AIDS 1997;11:1075-88.
45. Mellors JW, Rinaldo CR Jr, Gupta P, White RM, Todd JA, Kingsley LA. Prognosis in HIV-1 infection predicted by the quantity of virus in plasma. Science 1996;272:1167-70. [Erratum, Science 1997;275:14.]
46. Haigwood NL, Watson A, Sutton WF, et al. Passive immune globulin therapy in the SIV/macaque model: early intervention can alter disease profile. Immunol Lett 1996;51:107-14.
47. Smith MW, Dean M, Carrington M, et al. Contrasting genetic influence of CCR2 and CCR5 variants on HIV-1 infection and disease progression: Hemophilia Growth and Development Study (HGDS), Multicenter AIDS Cohort Study (MACS), Multicenter Hemophilia Cohort Study (MHCS), San Francisco City Cohort (SFCC), ALIVE Study. Science 1997;277:959-65.
48. Huang Y, Paxton WA, Wolinsky SM, et al. The role of a mutant CCR5 allele in HIV-1 transmission and disease progression. Nat Med 1996;2: 1240-3.
49. Cao Y, Qin L, Zhang L, Safrit J, Ho DD. Virologic and immunologic characterization of long-term survivors of human immunodeficiency virus type 1 infection. N Engl J Med 1995;332:201-8.
50. Pantaleo G, Menzo S, Vaccarezza M, et al. Studies in subjects with long-term nonprogressive human immunodeficiency virus infection. N Engl J Med 1995;332:209-16.
51. Klein MR, van Baalen CA, Holwerda AM, et al. Kinetics of Gag-specific cytotoxic T lymphocyte responses during the clinical course of HIV-1 infection: a longitudinal analysis of rapid progressors and long-term asymptomatics. J Exp Med 1995;181:1365-72.
52. Rinaldo C, Huang X-L, Fan ZF, et al. High levels of anti-human immunodeficiency virus type 1 (HIV-1) memory cytotoxic T-lymphocyte activity and low viral load are associated with lack of disease in HIV-1-infected long-term nonprogressors. J Virol 1995;69:5838-42.
53. Pantaleo G, Demarest JF, Schacker T, et al. The qualitative nature of the primary immune response to HIV infection is a prognosticator of disease progression independent of the initial level of plasma viremia. Proc Natl Acad Sci U S A 1997;94:254-8.
54. Kirchhoff F, Greenough TC, Brettler DB, Sullivan JL, Desrosiers RC. Absence of intact *nef* sequences in a long-term survivor with nonprogressive HIV-1 infection. N Engl J Med 1995;332:228-32.
55. Deacon NJ, Tsykin A, Solomon A, et al. Genomic structure of an attenuated quasi species of HIV-1 from a blood transfusion donor and recipients. Science 1995;270:988-91.
56. Dorrucci M, Rezza G, Vlahov D, et al. Clinical characteristics and prognostic value of acute retroviral syndrome among injecting drug users: Italian Seroconversion Study. AIDS 1995;9:597-604.
57. Henrard DR, Phillips JF, Muenz LR, et al. Natural history of HIV-1 cell-free viremia. JAMA 1995;274:554-8.
58. Balslev E, Thomsen HK, Weismann K. Histopathology of acute human immunodeficiency virus exanthema. J Clin Pathol 1990;43:201-2.
59. Ho DD, Rota TR, Schooley RT, et al. Isolation of HTLV-III from cerebrospinal fluid and neural tissues of patients with neurologic syndromes related to the acquired immunodeficiency syndrome. N Engl J Med 1985; 313:1493-7.
60. Niu MT, Stein DS, Schnittman SM. Primary human immunodeficiency virus type 1 infection: review of pathogenesis and early treatment intervention in humans and animal retrovirus infections. J Infect Dis 1993;168:1490-501.
61. Quinn TC. Acute primary HIV infection. JAMA 1997;278:58-62.
62. Tindall B, Cooper DA, Donovan B, Penny R. Primary human immunodeficiency virus infection: clinical and serologic aspects. Infect Dis Clin North Am 1988;2:329-41.
63. Kinloch-de Loes S, de Saussure P, Saurat JH, Stalder H, Hirschel B, Perrin LH. Symptomatic primary infection due to human immunodeficiency virus type 1: review of 31 cases. Clin Infect Dis 1993;17:59-65.
64. Tindall B, Barker S, Donovan B, et al. Characterization of the acute clinical illness associated with human immunodeficiency virus infection. Arch Intern Med 1988;148:945-9.
65. Busch MP, Lee LL, Satten GA, et al. Time course of detection of viral and serologic markers preceding human immunodeficiency virus type 1 seroconversion: implications for screening of blood and tissue donors. Transfusion 1995;35:91-7.
66. von Sydow M, Gaines H, Sonnerborg A, Forsgren M, Pehrson PO, Strannegard O. Antigen detection in primary HIV infection. BMJ 1988; 296:238-240. [Erratum, BMJ 1988;296:525.]
67. Henrard DR, Phillips J, Windsor I, et al. Detection of human immunodeficiency virus type 1 p24 antigen and plasma RNA: relevance to indeterminate serologic tests. Transfusion 1994;34:376-80.
68. Busch MP, Satten GA. Time course of viremia and antibody seroconversion following human immunodeficiency virus exposure. Am J Med 1997;102:Suppl 5B:117-24.
69. Michael NL, Brown AE, Voigt RF, et al. Rapid disease progression without seroconversion following primary human immunodeficiency virus type 1 infection — evidence for highly susceptible human hosts. J Infect Dis 1997;175:1352-9.
70. Carpenter CC, Fischl MA, Hammer SM, et al. Antiretroviral therapy for HIV infection in 1997: updated recommendations of the International AIDS Society–USA panel. JAMA 1997;277:1962-9.
71. Kinloch-de Loës S, Hirschel BJ, Hoen B, et al. A controlled trial of zidovudine in primary human immunodeficiency virus infection. N Engl J Med 1995;333:408-13. [Erratum, N Engl J Med 1995;333:1367.]
72. Lafeuillade A, Poggi C, Tamalet C, Profizi N, Tourres C, Costes O. Effects of a combination of zidovudine, didanosine, and lamivudine on primary human immunodeficiency virus type 1 infection. J Infect Dis 1997; 175:1051-5.
73. Perrin L, Markowitz M, Calandra G, Chung M, MRL Acute HIV Infection Study Group. An open treatment study of acute HIV infection with zidovudine, lamivudine and indinavir sulfate. In: Program and abstracts of the Fourth Conference on Retroviruses and Opportunistic Infections, Washington, D.C., January 22–26, 1997:108. abstract.
74. Hecht FM, Chesney MA, Busch MP, Rawal BD, Staprans SI, Kahn JO. Treatment of primary HIV with AZT, 3TC and indinavir. In: Program and abstracts of the Fifth Conference on Retroviruses and Opportunistic Infections, Chicago, February 1–5, 1998:189. abstract.
75. Finzi D, Hermankova M, Pierson T, et al. Identification of a reservoir for HIV-1 in patients on highly active antiretroviral therapy. Science 1997; 278:1295-300.
76. Wong JK, Hezareh M, Gunthard HF, et al. Recovery of replication-competent HIV despite prolonged suppression of plasma viremia. Science 1997;278:1291-5.

Downloaded from www.nejm.org at VA LIBRARY NETWORK on August 16, 2004.
Copyright © 1998 Massachusetts Medical Society. All rights reserved.