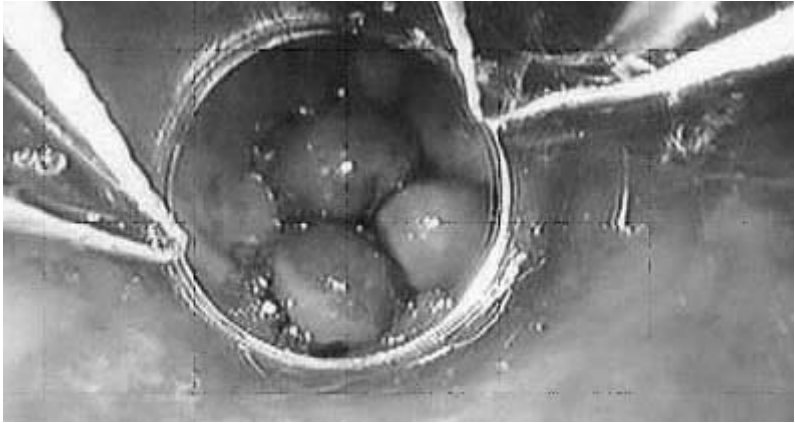


## Varices—A complication of alcoholic liver disease



View of varices in the esophagus, a consequence of liver disease, using endoscopy. These dilated veins are being banded to prevent gastrointestinal bleeding.

Source: Marsano, L.S. et al. Diagnosis and treatment of alcoholic liver disease and its complications. *Alcohol Research & Health* 27(3):247–256, 2003.

Prepared: February 2005